

FIRST RECORD OF *CALODIUM HEPATICUM* AND *TAENIA TAENIAEFORMIS* LIVER INFECTION IN WILD NORWAY RATS (*RATTUS NORVEGICUS*) IN SERBIA

MILENA KATARANOVSKI^{1,2}, LIDIJA ZOLOTAREVSKI³, SANDRA BELIJ¹, IVANA MIRKOV¹,
JELENA STOŠIĆ¹, ALEKSANDRA POPOV¹ and D. KATARANOVSKI^{1,4}

¹University of Belgrade, Institute for Biological Research "Siniša Stanković", Department of Ecology, 11060 Belgrade, Serbia

²University of Belgrade, Faculty of Biology, Institute of Physiology and Biochemistry, 11000 Belgrade, Serbia

³Military Medical Academy, Institute for Pathology, 11000 Belgrade, Serbia

⁴University of Belgrade, Faculty of Biology, Institute of Zoology, 11000 Belgrade, Serbia

Abstract - The nematode *Calodium hepaticum* and the cestode *Taenia taeniaeformis* are zoonotic helminths primarily found in the liver of common wild rats. Most reports on these helminth species with cosmopolitan distribution are from Asia, and there is paucity of data for Europe. Wild Norway rats (*Rattus norvegicus*) from urban and suburban habitats of the Belgrade area were examined for the presence of *Calodium hepaticum* and *Taenia taeniaeformis* larvae liver infections. The presence of visible cysts and a histomorphology of parasite-related inflammatory liver responses were sought as signs of infection. The total prevalence of infection was 10.9% (*C. hepaticum*) and 29.9% (*T. taeniaeformis*), with no differences between the sexes. No difference in the annual prevalence of both helminth species was noted. Data obtained in this study provide new information relevant to wild Norway rats as sources of *C. hepaticum* and *T. taeniaeformis* liver infection in this geographic area, and, in a wider context, in Europe.

Key words: Wild Norway rats, *Calodium hepaticum*, *Taenia taeniaeformis*, liver inflammation

UDC 599.323.4(497.11):616.98

INTRODUCTION

The Norway rat *Rattus norvegicus* (Berkenhout 1769) and the black rat *Rattus rattus* (Linnaeus 1758) are common rodent species with a wide distribution, mostly in urban and suburban habitats (Kataranovski, 1999). Because of their high ability to harbor many zoonotic agents (Bradshaw, 1999; Battersby et al., 2002; Easterbrook et al., 2007) wild rats play a significant role as definitive and/or intermediate hosts for vector-borne animal and human diseases.

The nematode *Calodium hepaticum* (Bancroft 1893) (syn. *Capillaria hepatica*) and the cestode *Taenia taeniaeformis* (Batsch 1786) (syn. *Hydatigera taeniaeformis*) are zoonotic helminths primarily found in the rat liver (Bancroft 1893, Luttermoser 1936, Firlotte 1948, Layne 1968, Liat and others 1977). The life cycle of *C. hepaticum* is direct and takes place in the liver of a single host (Calle, 1961). Studies in rats have shown

that worms of both sexes are found within the liver parenchyma, where they live and produce eggs. Unembryonated eggs are released into the environment after: 1) death and decomposing of the host; 2) cannibalism; or 3) predation by a rat (carrier) or another animal (intercalated host). Under favorable environmental circumstances (appropriate temperature and humidity) the ova embryonate and become infective. Following ingestion of embryonated ova, the free first-stage larvae hatch in the intestine and migrate, *via* the portal vein, into the liver, where they become mature worms and mate. After mating, the worms die and the females free thousands of ova into the liver. These ova do not undergo development (they remain unembryonated) and remain in the liver until the death of the host.

Wild common rats act as intermediate hosts for *Cysticercus fasciolaris*, the larval stage of cestode *T. taeniaeformis* (Firlotte, 1948). Carnivores of the

families Felidae, Canidae and Mustelidae are definitive hosts for this parasite, passing embryonated eggs in their feces (Abuladze, 1964; Schmidt, 1986). Ingestion of embryonated eggs by rats or other rodents results in them hatching in the small intestine and passing as embryos *via* portal circulation, to the liver, where they develop into infective larvae (Singh and Rao, 1967). The ingestion of the infective rat liver leads to transmission to a definitive host.

Both *C. hepaticum* and *T. taeniaeformis* helminth parasites have been noted worldwide, but with variable prevalence of infection in wild rats. Most numerous reports for *C. hepaticum* are from Asia, where a high (>50%-100%) (Claveria et al., 2005; Tung et al., 2009), moderate (>20%) (Seong et al., 1995) and low (<20%) (Yang and Lu, 2000; Namue and Wongsawad, 1997) prevalence of *C. hepaticum* has been noted in wild Norway rats and/or black rats (*Rattus rattus*). A high prevalence of more than 80% (Farhang-Azad, 1977; Conlogue et al., 1979; Easterbrook et al., 2007) was noted in the city of Baltimore, Maryland, USA. It has been recorded in the wild rats of Africa, with a low prevalence of 15.8% in Norway rats in Egypt (El-Nassery et al., 1991) and in 6.2% in black rats in Ethiopia (Farhang-Azad and Schlitter, 1978). In Europe, *C. hepaticum* infection has been noted in Norway rats with low (<2.9%) in Croatia (Stojcevic et al., 2002) to moderate prevalence (41-44%) in England (Webster and MacDonald, 1995), France (Davoust et al., 1997) and Italy (Ceruti et al., 2001). Hepatic capillariasis was not recorded in wild rats from Poland (Okulewicz et al., 2003).

T. taeniaeformis is also considered to be a species with cosmopolitan geographic distribution (Miyazaki, 1991). According to available literature, it is recorded in black rats in Asia (Seo et al., 1964; Seo et al., 1968; Seong et al., 1995; Claveria et al., 2005; Singla et al., 2008), in Norway rats in Canada (Firlotte, 1948) and the USA (Andrews and White, 1936) and in both black and Norway rats in New Zealand (McKenna, 1997). There are only two reports on *T. taeniaeformis* infection of wild Norway rats in Europe (Webster and MacDonald, 1995; Battersby et al., 2002).

As the primary and definitive hosts for *C. hepaticum* (Luttermoser, 1936; Layne, 1968; Liat et al., 1977) wild common rats can act as the main reservoirs of infection with this parasitic nematode. The bioavailability of *T. taeniaeformis* larvae in wild rats to other hosts which, through a predator-prey relationships, maintain and spread infection, is an important aspect of infection with this helminth. Humans are accidental hosts of *C. hepaticum*. Up to 2007, 38 cases of infection in humans have been reported worldwide (Nabi et al., 2007). Human infections with *T. taeniaeformis* are rare, and only several cases have been reported (Hoberg, 2002). However, the lack of accurate diagnostics makes this parasitosis more serious than expected.

Although the importance of wild rats as reservoirs of helminthic parasites is long known (Firlotte, 1948), scientific literature related to wild rat-borne liver infections is scant. The screening of helminthic liver infections is usually part of large-scale helminth parasite surveys in wild rats. Such studies are being conducted in various geographic areas, with no data on population characteristics such as sex index presented. Infection is mainly evaluated by prevalence, with other descriptors of parasite infection seldom provided, so that the extent to which rats carry these zoonotic helminth species is not largely known. Moreover, the histopathology of the helminth-related host liver response mirroring inflammatory/immune activity relevant for parasite eradication is rarely presented.

The aim of this study is to explore the presence and characteristics of *C. hepaticum* and *T. taeniaeformis* liver infection in wild Norway rats from the Belgrade area, Serbia. Wild *Rattus norvegicus* is the dominant rat species in this area (Kataranovski, 1999) and represents an important pest rodent species (Kataranovski and Kataranovski, 2006). The presence of visible cysts as well as histomorphological signs of a parasite-related inflammatory liver response were sought as signs of parasite infection. A survey of infection was conducted over a two-year period in urban and suburban habitats from the Belgrade area. Rats of both sexes were examined in order to get information concerning the contribution

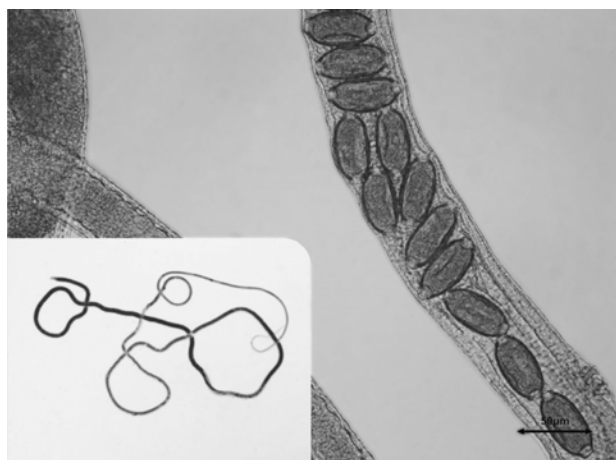


Fig. 1. Ovoid, bipolar eggs inside parasite. Female parasite (insert)

of gender to infection. Data obtained give new information relevant for wild Norway rats as sources of *C. hepaticum* and *T. taeniaeformis* liver infection in this geographical area and, in a wider context, in Europe.

MATERIALS AND METHOD

Animal collection

The rats were collected by live snap traps from different localities (urban or suburban/semirural/rural) of the Belgrade area (44°N, 20°E, approximate geometric center of Belgrade 44°49'14"N, 20°27'44"E) from February to November during two consecutive years (2007 and 2008). The animals were transported to the animal facility of the Institute for Biological Research "Sinisa Stankovic", Belgrade and examined not later than 72 hours after trapping. Animal procedures were carried out in adherence to the Ethical Committee of the Institute. The rats were fed commercial rodent feed and had access to water *ad libitum*.

Necropsy procedures

The animals were euthanized by barbiturate anesthesia overdose. Body weight measurements were done by using a balance with an error margin of +/-0.1 g. The livers were removed, cleaned of extraneous tissue and measured using a precise balance (+/-0.01 g).

Parasite examination

Gross examination of the liver was conducted in order to screen for the presence of *C. hepaticum* or *T. taeniaeformis* infection. *C. hepaticum* adults and eggs were visible as yellowish-white lesions. The female parasites containing numerous ovoid eggs, with bipolar caps and radial striation on the shell (Fig. 1), were isolated from the infected livers. The intensity of infection was classified based on the degree of liver involvement described by Conlogue et al., (1979) as heavy (lesions involving more than half of the liver), moderate (less than half of the liver involved) and slight (involvement of a single lobe). The livers in which white spots were noted were cut into slices to look for cysts that could not be detected at surface. The larval cestodes were counted and identified according to Genov (1984) and Schmidt (2001). According to Bush et al., (1997) *T. taeniaeformis* infection was described by using quantitative descriptors of parasite infection including prevalence (P), mean intensity of infection (MI) and mean abundance of infection (MA). Prevalence is calculated as the number of infected hosts divided by the number of examined hosts. The mean intensity of infection is the total number of parasites found in the sample (individuals infected) divided by the number of infected hosts. The mean abundance of infection is the total number of individuals of a parasite divided by the total numbers of hosts examined (including both infected and uninfected hosts). According to Kisieleska (1970) the index of infection (I) is calculated as $I = AxB/C^2$, where A is the total number of larval cestodes, B is number of hosts infected with the *T. taeniaeformis* larvae, and C is the total numbers of host examined.

Liver histology

All livers were fixed in 4% formalin (pH 6.9). After processing, the tissue was embedded in paraffin wax for sectioning at 5 µm. Hematoxylin and eosin (H&E)-stained histology slides were subsequently analyzed by light microscopy for the presence of *C. hepaticum* eggs, for the characteristic parasite-related tissue lesions and for inflammatory liver response to infection.

Data display and analysis

Data are expressed as the prevalence (P%) of infection (for both *C. hepaticum* and *T. taeniaeformis*) and as the index (I), mean intensity (MI) and mean abundance (MA±S.E.) of infection (for *T. taeniaeformis*). Statistical analysis was performed using the statistical software package STATISTICA 7.0 (StatSoft Inc., Tulsa, Oklahoma, USA). Significance was defined by the Mann-Whitney U test (liver mass and mean abundance of infection).

RESULTS

General animal data

A total of 147 rats caught in the Belgrade area during 2007 and 2008 were examined in the present study. Approximately similar numbers of animals of both sexes were caught during this period (67 males and 80 females). Physical examination of the animals provided an indication of the body condition and apparent health. No significant differences in liver weight were detected between the infected (3.79±0.5 g and 4.59±1.0 g, males and females respectively) and non-infected rats (3.96±0.9 g and 4.26±0.8 g, males and females respectively).

Quantitative indices of liver infection

Gross morphological inspection revealed morphologically visible yellowish nodules/cysts containing *C. hepaticum* in the livers of wild Norway rats. Slight infection (involvement of a single liver lobe) was noted in all the rats with *C. hepaticum* with the exception of one female, where a moderate degree of infection (less than half of the liver involved) was noted. No heavy infection was noted in the captured rats. A histological examination of the livers confirmed *C. hepaticum* infection in the rats. A relatively low prevalence of infection (16/147; 10.9%) was noted in the captured rats, with no differences between the sexes (5/67; 7.5% in males and 11/80; 13.8% in females). No differences in the

annual prevalence of *C. hepaticum* infection (9/81 x 100 = 11.1% in 2007 and 7/66 x 100 = 10.6% in 2008) was noted.

Quantitative indices of liver *T. taeniaeformis* infection of wild Norway rats are presented in Table 1. No differences in annual prevalence of *T. taeniaeformis* larvae infection (21/71 x 100 = 29.6% in 2007 and 23/76 x 100 = 30.3% in 2008) was noted. There were no animals which harbored *C. hepaticum* and *T. taeniaeformis* simultaneously.

Histology of liver infection

The histological analysis of the livers of rats infected with *C. hepaticum* revealed a granulomatous tissue reaction with different stages of fibrocellular tissue remodeling. Early liver changes in the form of a fibrous inflammatory reaction surrounding the eggs of *C. hepaticum* were found in some animals (Fig. 2a). In the livers of some of the rats chronic progressing lesions with loss of parenchyma due to the multifocal nodular coalescing areas of granulomatous reaction were noted (Fig. 2b). Parasite destruction within a dense fibrocellular capsule often associated with neutrophil infiltration could be seen. Fibrocellular septae disassociating the hepatic parenchyma into irregular portions were noted in the vicinity of the granulomatous reaction. Less pronounced fibrocellular parenchymal remodeling was noted in areas unassociated with granulomatous reaction. In these areas, signs of immune-relevant parasite-related activity such as prominent Kupffer cells were noted in the livers of some of the infected animals (Fig. 2c). Additionally, a moderate to intense dilatation of the central hepatic vein and surrounding sinusoids could be noted in the livers of some of the infected animals (Fig. 2d).

None of the fibrotic changes characteristic for cysticercus larvae encapsulation were noted in the animals with *T. taeniaeformis* infection. Signs of inflammation including periportal eosinophil infiltrates (Fig. 3a), micro-abscesses (Fig. 3b), sinusoid widening and prominent Kupffer cells were noted.

Table 1. Quantitative indices of liver *T. taeniaeformis* infection in wild Norway rats of different age from different habitats

	n	Z	P%	I	MI	MA ± SE
Total	44	147	29.9%	0.120	1.34	0.360±0.051
Males	23	67	34.3%	0.150	1.30	0.418±0.080
Females	21	80	26.3%	0.095	1.38	0.312±0.066

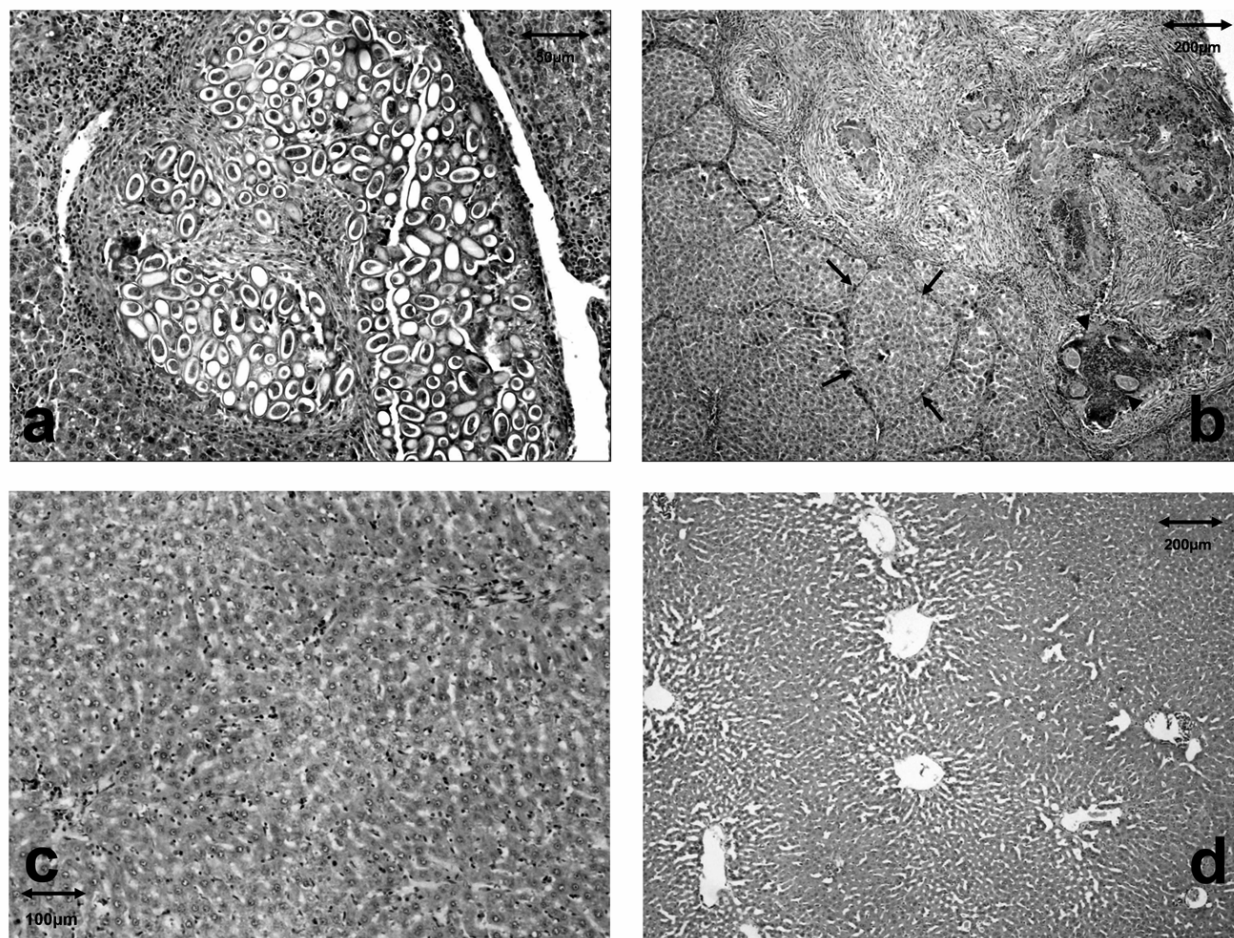


Fig. 2. a) Granulomatous formations containing *C. hepaticum* eggs; b) Multifocal granulomatous reaction around *C. hepaticum* and fibrous remodeling in the liver parenchyma. Septal fibrosis (arrows). Neutrophil infiltration associated with parasite destruction (arrowheads); c) Prominent Kupffer cells; d) Central hepatic vein and sinusoid dilatation

DISCUSSION

The prevalence of *C. hepaticum* and *T. taeniaeformis* liver infections in the wild Norway rats from the Belgrade area, Serbia, was explored in this study.

Basic morphohistological characteristics of liver infection were employed in the evaluation/confirmation of the presence of *C. hepaticum* infection and in the description of host liver response to the presence of *C. hepaticum* and *T. taeniaeformis*. To

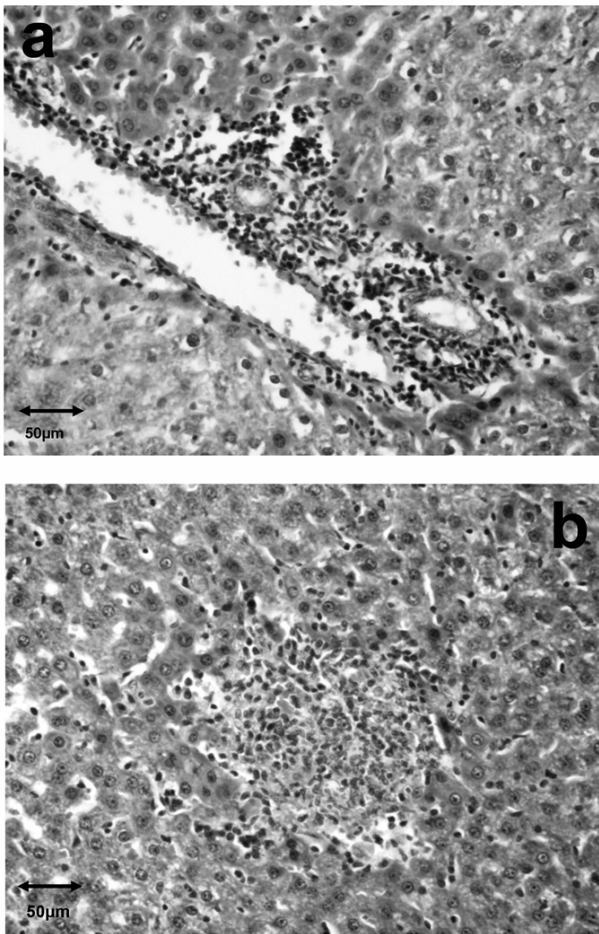


Fig. 3. a) Periportal eosinophil infiltrates; b) Neutrophilic micro-abscesses

our knowledge, this is the first report on the infection in rats with the helminths *C. hepaticum* and *T. taeniaeformis* in this geographic area.

Compared to the data for other European countries the prevalence of *C. hepaticum* infection in Serbia is lower than that found in the United Kingdom (Webster and MacDonald, 1995), France (Davoust et al., 1997) or Italy (Ceruti et al., 2001), but is higher compared to data from Croatia, where prevalence of 1.95% – 3.91% has been noted (Stojcevic et al., 2002) and from Poland, where no infection has been noted (Okulewicz et al., 2003). As suggested by Davis (1951) and Farhang-Azad

(1977), the rates of infection of rats with *C. hepaticum* might depend on population densities of *R. norvegicus*. A continuous supply of *C. hepaticum* eggs and the increased probability of contact with infective eggs in a high density population might account for a higher parasite burden in the host. A program of systematic deratization which has been regularly conducted twice a year in the Belgrade area (Hrgovic et al., 1991) might account for the relatively low prevalence of *C. hepaticum* infection.

The absence of differences in the annual prevalence of infection in our study is in accordance with published data which have explored this matter (Farhang-Azad, 1977; Conlogue et al., 1979). Lack of sex-biased *C. hepaticum* infection is in agreement with the data from other urban habitats (Childs et al., 1988; Easterbrook et al., 2007).

A low intensity of *C. hepaticum* infection, with only one animal with moderate liver involvement (according to the description of the degree of liver involvement presented by Conlogue et al., (1979)) was noted in the wild Norway rats from the Belgrade area. This could be related to the low prevalence of infection, as more severe infection was noted in cities where a higher prevalence was noted. In the city of Hartford, Connecticut, with 81% infected rats, 31% had moderate and 9% heavy infection (Conlogue et al., 1979). According to the survey in the city of Milan, Italy, where a prevalence of 36% infected rats was noted, a moderate degree of infection was noted in 71% and severe in 17% of infected animals (Ceruti et al., 2001).

To our knowledge there are no systematic studies of *T. taeniaeformis* liver infection in wild Norway rats. The prevalence of infection in wild rats from semirural/rural and urban habitats noted in our study is higher compared to data for Europe, e.g. farms in the UK (11%) (Webster and MacDonald, 1995) and the city of London (0%) (Battersby et al., 2002). The higher prevalence of *T. taeniaeformis* in rats from Belgrade could be connected with the higher accessibility of the hosts to infection with parasite eggs which can remain infective in the environment for long periods. In the study area, potential definitive

hosts would be carnivores such as *Felis domestica* and *Canis familiaris*, which commonly prey upon wild rats. The presence of both feral and stray cats in the habitats explored (Kulisic et al., 1998; Nikolic et al., 2008) in our study might have increased the probability of encountering this helminth. Predator-prey interactions between wild Norway rats and feral cats or dogs increase the probability of encounters with the helminth, thus maintaining the life cycle of the parasite. In addition, the presence of farm-like households in the suburban areas of Belgrade city, where it is customary to have several working dogs as well as cats as household pets, might also have contributed to the high prevalence of the parasite. The contribution of population density of *R. norvegicus* in urban and suburban environments cannot be accounted for the relatively high prevalence of *T. taeniaeformis* infection, particularly as deratization measures maintain low numbers of rats. The prevalence of *T. taeniaeformis* is most likely connected to the high abundance of definitive hosts in these environments.

A granulomatous reaction in the liver is a common histopathological finding in naturally infected rats (Davoust et al., 1997; Ceruti et al., 2001). These focal inflammatory lesions are determined by the presence of live, dying or dead worms and their eggs. Infiltration of neutrophils is associated with encapsulated parasite destruction (Ceruti et al., 2001). Focal parasitic lesions are often associated with process of septal fibrosis associated with *C. hepaticum* infection (Ferreira and Andrade, 1993). Septal fibrosis is a commonly seen variant of hepatic fibrosis which is represented by thin, strait fibrocellular/fibrous tissue septa that dissect the liver parenchyma into hepatic nodules. Experimental data obtained after *C. hepaticum* egg injection showed that the presence of focal (granulomatous) lesions are necessary for the development of septal fibrosis (Santos et al., 2001). Although focal lesions and septal fibrosis run on independent pathways, the induction of the latter is triggered during early infection (Gomes et al., 2006). An experimental infection of laboratory stocks of Norway rats revealed the immunological basis of septal fibrosis of the liver in infected rats (Lemos et al., 2003). A histologi-

cally-based case report on *C. hepaticum* liver infection in the Norway rat showed immunologically-relevant activity of macrophages, mast cells and myofibroblasts in the pseudolobules formed by fibrous septae (Jeong et al., 2008). Prominent Kupffer cells noted in areas unassociated with granulomas closely parallel these findings. Periportal lymphoid and neutrophil infiltration, dilatation of the central hepatic vein and sinusoids of various intensity in the livers of infected animals are associated with infection (Ceruti et al., 2001). These changes, in our opinion, could be associated with *C. hepaticum* first-stage larva migration.

The absence of larvae encapsulated within the liver as well as histologically evident signs of immune/inflammatory activity in the livers of rats infected with *T. taeniaeformis* point out the capability of these animals to respond to infective challenge. Micro-abscesses composed of neutrophils and/or eosinophil in the livers of rats infected with *T. taeniaeformis* as well as prominence of macrophages (Kupffer cell) mirror the activity of these cells engaged in such a response. The presented findings (in naturally infected rats) are in line with data from experimentally infected rats which showed an eosinophilic response and neutrophil infiltration in the liver of these rats (Ansari and Williams, 1976; Leid, 1977). The presence of such immune-related activity in the liver of rats infected with *T. taeniaeformis* larvae is in accordance with data which demonstrates the capacity of taeniid parasites to stimulate the immune response to an invasive larval stage (Bogh et al., 1990).

In conclusion, this study has demonstrated the prevalence and characteristics of *C. hepaticum* and *T. taeniaeformis* liver infection in wild Norway rats. The presented data indicate that rats can be sources of these zoonotic infections in urban/suburban environments. As such, they might be useful in understanding the sanitary risks of zoonoses carried by wild rats and in their management.

Acknowledgment - This study was supported by the Ministry of Science and Technological Development of the Republic of Serbia, Grant # 143038.

REFERENCES

- Abuladze, K. I. (1964). Taeniata of animals and man and diseases caused by them. In: *Essentials of cestodology*. (In Russian) Ed K.I. Skrjabin Moscow, Nauka, 528.
- Andrews, J. and H. F. White, (1936). An epidemiological study of protozoa parasites in wild rats in Baltimore, with special reference to *Entamoeba histolytica*. *American Journal of Epidemiology* **24**, 184-206.
- Ansari, A. and J. F. Williams, (1976). The eosinophilic response of the rat to infection with *Taenia taeniaeformis*. *The Journal of Parasitology* **62**, 728-736.
- Bancroft, T. L. (1893). On the with-worm of the rats liver. *Journal and Proceedings of the Royal Society of New South Wales* **27**, 86-90.
- Battersby, S. A., Parsons, R. and J. P. Webster, (2002). Urban rat infestations and the risk to public health. *Journal of Environmental Health Research* **1**, 4-12.
- Bogh, H. O., Lightowers, M. W., Sullivan, N. D., Mitchell, G. F. and M. D. Rickard, (1990). Stage-specific immunity to *Taenia taeniaeformis* infection in mice. A histological study of the course of infection in mice vaccinated with either oncosphere or metacystode antigens. *Parasite Immunology* **12**, 153-162.
- Bradshaw, J. (1999). Know your enemy. *Environmental Health* **107**, 126-128.
- Bush, A. O., Lafferty, K. D., Lotz, J. M. and A. W. Shostak, (1997). Parasitology meets ecology on its own terms: Margolis et al, revisited. *The Journal of Parasitology* **83**, 575-583.
- Calle, S. (1961). Parasitism of *Capillaria hepatica*. *Pediatrics* **27**, 648-655.
- Ceruti, R., Sonzogni, O., Origgi, F., Vezzoli, F., Cammarata, S., Giusti, A. M. and E. Scanziani, (2001). *Capillaria hepatica* infection in wild brown rats (*Rattus norvegicus*) from the urban area of Milan, Italy. *Journal of Veterinary Medicine* **48**, 235-240.
- Childs, J. E., Glass, G. E. and G. W. Korch, (1988). The comparative epizootiology of *Capillaria hepatica* (Nematoda) in urban rodents from different habitats of Baltimore, Maryland. *Canadian Journal of Zoology* **66**, 2769-2775.
- Claveria, F. G., Causapin, J., Anaceta De Guzman, M., Toledo, M. G. and C. Salibay, (2005). Parasite biodiversity in *Rattus* spp. caught in wet markets. *The Southeast Asian Journal of Tropical Medicine and Public Health* **36**, 146-148.
- Conlogue, G., Foreyt, W., Adess, M. and H. Levine, (1979). *Capillaria hepatica* (Bancroft) in selected rat populations of Hartford, Connecticut, with possible public health implications. *The Journal of Parasitology* **65**, 105-108.
- Davis, E. D. (1951). The relation between the levels of population and the prevalence of *Leptospira*, *Salmonella* and *Capillaria* in Norway rats. *Ecology* **32**, 465-468.
- Davoust, B., Boni, M., Branquet, D., Lahitte, J. D. D. and G. Martet, (1997). Research on three parasitic infestations in rats captured in Marseille: evaluation of the zoonotic risk. *Bulletin de l'Académie Nationale de Médecine* **181**, 187-195.
- Easterbrook, J. D., Kaplan, J. B., Vanasco, N. B., Reeves, W. K., Purcell, R. H., Kosoy, M. Y., Glass, G. E., Watson, J. and S. L. Klein, (2007). A survey of zoonotic pathogens carried by Norway rat in Baltimore, Maryland, USA. *Epidemiology and Infection* **135**, 1192-1199.
- El-Nassery, S. F., El-Gebali, W. M. and N. Y. Oweiss, (1991). *Capillaria hepatica*: an experimental study of infection in white mice. *Journal of the Egyptian Society of Parasitology* **22**, 467-478.
- Farhang-Azad, A. (1977). Ecology of *Capillaria hepatica* (Bancroft 1893) (Nematoda). 1. Dynamics of infection among Norway rat populations of the Baltimore Zoo, Baltimore, Maryland. *The Journal of Parasitology* **63**, 117-122.
- Farhang-Azad, A. and D. A. Schlitter, (1978) *Capillaria hepatica* in small mammals collected from Shoa province, Ethiopia. *Journal of Wildlife Diseases* **14**, 358-360.
- Ferreira, L. A. and Z. A. Andrade, (1993). *Capillaria hepatica*: a cause of septal fibrosis of the liver. *Memórias do Instituto Oswaldo Cruz* **88**, 441-447.
- Firlotte, W. R. (1948). A survey of the parasites of the brown Norway rat. *Canadian Journal of Comparative Medicine and Veterinary Science* **12**, 187-191.
- Genov, T. (1984). Helminths of Insectivorous Mammals and Rodents in Bulgaria. Bulgarian Academy of Science, Sofia, Bulgaria. 348.
- Gomes, A. T., Cunha, L. M., Bastos, C. G., Medrado, B. F., Assis, B. C. A. and Z. A. Andrade, (2006). *Capillaria hepatica* in rats: focal parasitic hepatic lesions and septal fibrosis run independent courses. *Memórias do Instituto Oswaldo Cruz* **101**, 895-898.
- Hoberg, E. P. (2002). *Taenia* tapeworms: their biology, evolution and socioeconomic significance. *Microbes and Infection* **4**, 859-866.
- Hrgovic, N., Vukicevic, Z. and D. Kataranovski, (1991). Economic importance of mouse-like rodents. In Control of Pest Rodent Populations-Deratization. (Ed. D. Perovic), Gornji Milanovac, Decje Novine, 81-90, (in Serbian)
- Jeong, W. I., Do, S. H., Hong, I. H., Ji, A. R., Park, J. K., Ki, M. R., Park, S. C. and K. S. Jeong, (2008). Macrophages, myofibroblasts and mast cells in a rat liver infected with *Capillaria hepatica*. *Journal of Veterinary Science* **9**, 211-213.

- Kataranovski, D. (1999). Distribution of the Norway rat *Rattus norvegicus* Berk., 1796 (Rodentia) in the territory of former and present Yugoslavia. Proceedings of an International Symposium: Contribution to the Zoogeography and Ecology of the Eastern Mediterranean Region. Hellenic Zoological Society. Athens, Greece, April 1 to 5, 1999, 99-104.
- Kataranovski, D. S., and M. V. Kataranovski, (2006) Excessive population control in protection of biodiversity (invited lecture). Proceedings of the 5th International Symposium: Biocides in Public Health and Environmental Protection. (Eds. V. B. Radonjic, D. L. Knezevic, S. S. Cetkovic), Belgrade, Serbia, October 1 to 6, 2006, 102-113.
- Kisielewska, K. (1970). Ecological organization of intestinal helminths groupings in *Clethrionomys glareolus* (Schreber, 1780) (Rodentia): I Structure and seasonal dynamics of helminths groupings in a host population in the Bialowieza National Park. *Acta parasitologica Polonica* **18**, 121-147.
- Kuliscic, Z., Pavlovic, I., Milutinovic, M. and N. Aleksic-Bakrac, (1998). Intestinal parasites of dogs and role of dogs in epidemiology of larva migrants in the Belgrade area. *Helminthologia* **35**, 78-82.
- Layne, J. N. (1968). Host and ecological relationship of the parasitic helminth *Capillaria hepatica* in Florida mammals. *Zoologica* **53**, 107-123.
- Leid, W. R. (1977). Immunity to the metacystode of *Taenia taeniaeformis* in the laboratory rat. *The American Journal of Tropical Medicine and Hygiene* **26**, 54-60.
- Lemos, Q. T., Magalhaes-santos, I. F. and Z. A. Andrade, (2003). Immunological basis of septal fibrosis of the liver in *Capillaria hepatica*-infected rats. *Brazilian Journal of Medical and Biological Research* **36**, 1201-1207.
- Liat, L. B., Fong, Y. L. and M. Krishnasamy, (1977). *Capillaria hepatica* infection of wild rodents in peninsular Malaysia. *The Southeast Asian Journal of Tropical Medicine and Public Health* **8**, 354-358.
- Luttermoser, G. W. (1936). A helminthological survey of Baltimore house rats (*Rattus norvegicus*). *American Journal of Epidemiology* **37**, 350-360.
- McKenna, P. B. (1997). Checklist of helminth parasites of terrestrial mammals in New Zealand. *New Zealand Journal of Zoology* **24**, 277-290.
- Miyazaki, I. (1991). Helminthic zoonoses. International Medical Foundation of Japan, Tokyo, 494.
- Nabi, F., Palaha, H. K., Sekhsaria, D. F. and A. Chiatale, (2007). *Capillaria hepatica* infestation. *Indian Pediatrics* **44**, 781-782.
- Namue, C. and C. Wongsawad, (1997). A survey of helminth infection in rats (*Rattus* spp) from Chiang Mai Moat. *The Southeast Asian Journal of Tropical Medicine and Public Health* **28**, 179-183.
- Nikolic, A., Dimitrijevic, S., Kazic-Radivojevic, S., Klun, I., Bobic, B. and O. Djurkovic-Djakovic, (2008). High prevalence of intestinal zoonotic parasites in dogs from Belgrade, Serbia-Short communication. *Acta Veterinaria Hungarica* **56**, 335-340.
- Okulewicz, A., Agnieszka, P., Hildebrand, J. and J. Okulewicz, (2003) *Calodium hepaticum* (Bancroft 1893) Moravec, 1982- capillaria with an atypical life cycle. *Wiadomości Parazytologiczne* **49**, 115-124.
- Santos, A. B., Tolention, J. R. M. and Z. A. Andrade, (2001). Pathogenesis of hepatic septal fibrosis associated with *Capillaria hepatica* infection in rats. *Revista da Sociedade Brasileira de Medicina Tropical* **34**, 503-506.
- Schmidt, G. D. (1986). Handbook of tapeworm identification. CRC Press, Boca Raton, Florida. 227.
- Schmidt, S. (2001). Investigation on the occurrence of *Capillaria hepatica* and metacystodes of Cyclophillida in wild mice in Germany. PhD thesis, Institute of Parasitology, Faculty of Veterinary Medicine, University of Leipzig, Germany. 145 (in German).
- Seo, B. S., Rim, H. J., Lee, C. W. and J. S. Yoon, (1964) Studies of the parasitic helminths of Korea. II Parasites of the rat, *Rattus norvegicus* EXRL, in Seoul, with the description of *Capillaria hepatica* (Bancroft, 1893) Travassos, 1915. *The Korean Journal of Parasitology* **2**, 55-62.
- Seo, B. S., Rim, H. J., Koo, B. Y., Hong, N. T. and J. S. Yoon, (1968). Studies of the parasitic helminths of Korea. III Nematodes and Cestodes of rodents. *The Korean Journal of Parasitology* **6**, 123-131.
- Seong, J. K., Hih, S., Lee, J. S. and Y. S. Oh, (1995). Helminths in *Rattus norvegicus* captured in Chunchon, Korea. *The Korean Journal of Parasitology* **33**, 235-237.
- Singh, B. B. and B. V. Rao, (1967). On the development of *Cysticercus fasciolaris* in albino rat liver and its reaction on the host tissue. *Ceylon Veterinary Journal* **15**, 121-129.
- Singla, L. D., Singla, N., Parshad, V. R., Juyal, P. D. and N. K. Sood, (2008). Rodents as reservoirs of parasites in India. *Integrative zoology* **3**, 21-26.
- Stojcevic, D., Marinculic, A. and Z. Mihajljevic, (2002) Prevalence of *Capillaria hepatica* in Norway rats (*Rattus norvegicus*). *Veterinarski arhiv* **72**, 141-149.
- Tung, K. C., Hsiao, F. C., Yang, C. H., Chou, C. C., Lee, W. M., Wang, K. S. and C. H. Lai, (2009). Surveillance of endoparasitic infections and the first report of *Physaloptera* sp. and *Sarcocystis* spp. in farm rodents and shrews in central Taiwan. *The Journal of Veterinary Medical Science* **71**, 43-47.

Webster, J. P. and D. W. Macdonald, (1995). Parasites of wild brown rats (*Rattus norvegicus*) on UK farms. *Parasitology* **111**, 247-255.

Yang, C. H. and K. H. Lu, (2000). Survey of *Angiostrongylus cantonensis* and *Capillaria hepatica* in field rodents in Taiwan. *Taiwan Journal of Veterinary Medicine and Animal Husbandry* **70**, 51-57.

ПРВИ НАЛАЗИ ИНФЕКЦИЈЕ ЈЕТРЕ ПАРАЗИТИМА *CALODIUM HEPATICUM* И *TAENIA TAENIAEFORMIS* КОД СИВОГ ПАЦОВА (*RATTUS NORVEGICUS*) У СРБИЈИ

МИЛЕНА КАТАРАНОВСКИ^{1,2}, ЛИДИЈА ЗОЛОТАРЕВСКИ³, САНДРА БЕЛИЈ¹, ИВАНА МИРКОВ¹, ЈЕЛЕНА СТОШИЋ¹, АЛЕКСАНДРА ПОПОВ¹ И Д. КАТАРАНОВСКИ^{1,4}

¹ Одељење за екологију, Институт за биолошка истраживања „Синиша Станковић“, Универзитет у Београду, 11060 Београд, Србија

² Универзитет у Београду, Биолошки факултет, Институт за физиологију и биохемију, 11000 Београд, Србија

³ Институт за патологију, Војно медицинска академија, 11000 Београд, Србија

⁴ Универзитет у Београду, Биолошки факултет, Институт за зоологију, 11000 Београд, Србија

Нематода *Calodium hepaticum* и цестода *Taenia taeniaeformis* су зоонотски хелминти који се налазе претежно у јетри пацова из природних популација. Највећи број података о инфекцији овим хелминтима широког распрострањења потиче из Азије, а мали је број података за Европу. У раду је испитивано присуство ових паразитских хелмината и карактеристике инфекције јетре код јединки сивог пацова, *Rattus norvegicus*, из урбаних и субурбаних станишта са подручја Београда. Присуство видљивих

циста и хистоморфолошке карактеристике запаљенске реакције изазване присуством паразита су праћене као знаци инфекције јетре. Укупна преваленца је била 10.9% (*C. hepaticum*) и 29.9% (*T. taeniaeformis*). Нису запажене разлике у преваленци инфекције међу половима, као и на годишњем нивоу. Ова студија је извор података о сивом пацову као извору инфекције јетре паразитима *C. hepaticum* и *T. taeniaeformis* на нашем географском подручју, и шире, у Европи.