

## ESTRADIOL AND GH CELLS: IMMUNOHISTOMORPHOMETRIC STUDY IN AN ANIMAL MODEL OF ANDROPAUSE

VERICA MILOŠEVIĆ<sup>1</sup>, SVETLANA TRIFUNOVIĆ<sup>1</sup>, B. FILIPOVIĆ<sup>1</sup>, BRANKA ŠOŠIĆ-JURJEVIĆ<sup>1</sup>,  
JASMINA PANTELIĆ<sup>1</sup>, FLORINA PERČINIĆ-POPOVSKA<sup>2</sup> and V. AJDŽANOVIĆ<sup>1</sup>

<sup>1</sup>University of Belgrade, Institute for Biological Research "Siniša Stanković", 11000 Belgrade, Serbia

<sup>2</sup>Faculty of Veterinary Medicine, 1000 Skopje, FYR of Macedonia

*Abstract* - Andropause, the culminating phase of ageing in males is characterized by the decline of the growth hormone (GH)/insulin-like growth factor 1 (IGF-1) axis that is responsible for somatic development. Estrogens on the other hand, assume a relevant somatic role, as well as the one in the pituitary. They are particularly interesting because of their therapeutic uses in certain common ageing-associated diseases. The aim of the present study was to examine the effects of subcutaneous treatment with estradiol, dipropionate on the immunohistomorphometric features of GH cells, in an animal model of the andropause. Sixteen-month-old Wistar rats were divided into sham-operated (**SO**), orchidectomized (**Orx**) and estradiol dipropionate-treated orchidectomized (**Orx+Edp**) groups. Estradiol dipropionate (0.625 mg/kg/day) was administered subcutaneously for three weeks while the **SO** and **Orx** groups received the vehicle alone. GH cells were identified by the peroxidase-antiperoxidase (PAP) immunohistochemical procedure. In the **Orx+Edp** group, GH cell volumes as well as the relative volume densities were significantly ( $p < 0.05$ ) decreased, by 27.4% and by 61.1%, respectively, in comparison with the same parameters of **SO** animals. Compared to the **Orx** animals, the cell volumes and relative volume densities of GH cells in **Orx+Edp** group were also significantly ( $p < 0.05$ ) decreased, by 23.2% and by 64.1%, respectively. It can be concluded that chronic estradiol dipropionate application in an animal in the andropause results in the suppression of immunohistochemical and morphometric parameters of pituitary GH cells.

*Key words:* Estradiol, GH cells, immunohistomorphometry, andropause

### INTRODUCTION

Ageing in males culminates in the andropause or "symptomatic late-onset hypogonadism" (Morales, 2004), which considers a number of symptoms related to the lack of androgens (Vance, 2003). The growth hormone (GH)/insulin-like growth factor 1 (IGF-1) axis, which is responsible for somatic development, is also reduced in advanced age (Thompson et al., 2003), thus affirming the concept of somatopause within andropause. Age-associated pituitary GH cell attenuation appears as the result of an imbalance between the hypothalamic release of somatostatin and

the growth hormone-releasing hormone (GHRH) (Epelbaum, 2008). These physiological changes result in manifestations such as frailty, increased fat mass and cardiovascular risk, reduced muscle mass and a generally impaired quality of life (Ceda et al., 2010; Di Somma et al., 2011).

Estrogens are very important mediators in skeletal growth and maturation during development in both genders, as well as in later bone mass maintenance (Grumbach and Auchus, 1999). It was suggested that estrogen deficiency might cause osteopenia and osteoporosis even at an earlier age

(Carani et al., 1997). In addition, estrogen induces insulin-mediated pituitary cells proliferation (Takahashi et al., 1994). Finally, the application of estrogen agonists, besides radio- and chemo-therapy, represents the classical hormonal approach in the therapy of prostate cancer that is frequent in advanced age (Tamella, 2004). Obviously, the estrogens play a relevant somatic role, as well as a role in the pituitary. They are especially of interest because of their therapeutic use in some common ageing diseases.

Considering pituitary GH cells as the operative component of the GH/IGF1 axis, as well as the functional decline of the axis with ageing, the aim of this study was to investigate the effects of subcutaneous treatment with estradiol dipropionate on the immunohistomorphometric features of GH cells in an animal model of andropause. Orchidectomy was performed to eliminate endogenous testosterone and estradiol from the hormonal milieu and their potential effects on the GH cells.

## MATERIALS AND METHODS

### *Animals and diets*

Sixteen-month-old (andropausal) male Wistar rats were used. The rats were bred in the Institute for Biological Research "Siniša Stanković", Belgrade, Serbia. The animals were housed one per cage, exposed to a 12 h light/dark cycle and kept at  $22\pm 2^\circ\text{C}$ . Two weeks before the experiment, the rats were given a soy-free diet, prepared in cooperation with the Department of Food, School of Veterinary Medicine, Belgrade, Serbia, and INSHRA PKB, Belgrade, Serbia, according to Picherit et al. (2000), with corn oil as the fat source.

The diet contained per 100 g: 20.3 g casein; 65 g carbohydrate (45 g cornstarch + 20 g sucrose); 5.2 g corn oil; 3.7 g fiber (crystalline cellulose); 1.5 g vitamin/mineral mix (calcium-phosphate deficient); 1.8 g calcium-phosphate dibasic; 1 g calcium carbonate; 1.5 g DL-methionine. Casein and crystalline cellulose were obtained from Alfa Aesar, Johnson Mat-

they GmbH & Co. KG, Karlsruhe, Germany; carbohydrate, oil, vitamin/mineral mix, calcium carbonate and calcium phosphate were from INSHRA PKB, Belgrade, Serbia, and DL-methionine was obtained from Sigma Chemical Company, St. Louis, MO, USA. Food and water were available *ad libitum*.

### *Animal treatments*

At the age of 15 months, the experimental animals were bilaterally orchidectomized (Orx) or sham-operated (SO) under Ketamine anesthesia (15mg/kg b.w.; Richter Pharma, Wels, Austria.). The recovery period lasted two weeks after the surgery. The orchidectomized rats were then divided into three groups of eight animals ( $n=8$ ) each. The first group was subcutaneously treated with estradiol dipropionate (Galenika, Belgrade, Serbia; **Orx+Edp**) at a dose of 0.625 mg/kg b.w., every day except on Sundays, for 3 weeks. The second (**Orx**) and third (**SO**) groups received a sterile olive oil (0.5 ml *per* animal), following the same schedule. All the animals were killed by decapitation under ether anesthesia (ether narcosis Ph. Iug. III., Lek, Ljubljana, Slovenia) 24 h after the last injection. The experimental protocols were approved by the Animal Care Committee of the Institute for Biological Research (Belgrade, Serbia) and were in conformity with the recommendation provided in the European Convention for the Protection of Vertebrate Animals used for Experimental and Other Scientific Purposes (ETS No. 123, Appendix A).

### *Light microscopy and immunocytochemistry*

The pituitary glands were excised, fixed in Bouin's solution for 48 h and embedded in paraplast. Serial 5- $\mu\text{m}$  thick tissue sections were deparaffinized in xylol and serial alcohol. GH was localized by the peroxidase-antiperoxidase complex (PAP) method of Sternberger et al. (1970). The endogenous peroxidase activity was blocked by incubation in 9 mmol (0.3%) hydrogen peroxide solution in methanol for 15 min at ambient temperature. Before the application of the specific primary antisera, nonspecific background staining was prevented by incubating the sections with nonimmune, *i.e.* normal, porcine serum diluted

with phosphate buffered saline (PBS) pH 7.4 for 60 min. Sections were then overlaid with appropriate dilutions of the specific primary antibodies (hGHantiser, Dako A/S, Glostrup, Denmark; diluted 1:200 in PBS) for 24 h at room temperature. This antibody strongly cross-reacts with rat GH (Milošević et al., 1994). After washing in PBS for 5 min, sections were incubated for 60 min with a secondary antibody, swine anti-rabbit IgG (DAKO, Glostrup, Denmark; diluted 1:100 in PBS); rinsed again in PBS for 5 min and then incubated with rabbit PAP complex (DAKO A/S, Glostrup, Denmark; diluted 1:100 in PBS), for 45 min. Binding sites were visualized using 0.05% diaminobenzidine (DAB; Serva, Heidelberg, Germany) and 0.03% hydrogen peroxide in a 0.2M TRIS-HCl buffer, pH 7.4. The sections were counterstained with hematoxylin and mounted in Canada balsam (Molar Chemicals KFT, Budapest, Hungary). For the control sections, the primary antibody was omitted and replaced by PBS, pH 7.4.

### *Morphometry*

Rat pituitaries were serially cut to 5  $\mu\text{m}$  thick sections. Two sections from the dorsal, three from the middle and two from the ventral part (seven sections, 20  $\mu\text{m}$  apart in total) of the rat pituitary glands were analyzed. The point counting method was used at an overall magnification of x1000 (Weibel, 1979). The  $M_{42}$  multipurpose test grid, inserted into the ocular of a Zeiss light microscope (Jena, Germany), was randomly positioned on the pituitary section at the beginning of counting. Counting was carried out on the following 50 test fields *per* section. Average values were calculated *per* pituitary *i.e.* *per* animal (7 sections, 350 test fields) and five pituitaries were analyzed *per* group. Cell volume ( $V_c$ ,  $\mu\text{m}^3$ ), volume of the nuclei ( $V_n$ ;  $\mu\text{m}^3$ ) and volume density (percentage of immunoreactive cells in  $\mu\text{m}^3$ ,  $V_{vc}$ ; %) were determined for GH-immunoreactive cells.

*The following parameters were counted:*

$P_n$  – the number of points hitting on nuclei of immunohistochemically-labeled cells inside the test field;

$P_{tc}$  – the number of points hitting on the cytoplasm of immunohistochemically-labeled cells inside the test field.

$N_n$  – the number of immunohistochemically-labeled cell nuclei inside the test field

The formula used for calculating the nuclear volumes was:

$$V_n = V_{vn} / N_v$$

The formula used for calculating the cell volume was:

$$V_c = 1 / N_v$$

$V_{vn}$  is the volume density of GH cell nuclei and  $N_v$  is the numerical density of GH cells. The nuclear volume density ( $V_{vn}$ ) provides information about the nuclear presence in the estimated cells and is calculated as follows:

$$V_{vn} = \Sigma P_n / \Sigma P_{tc}$$

Since rat GH cells are mononuclear,  $N_v$  corresponds to the number of cells per cubic millimeter, according to the formula:

$$N_v = (k/\beta) (N_A^{3/2} / V_{vn}^{1/2})$$

On the basis of earlier karyometric studies (Malendowicz, 1974), the shape coefficient  $\beta$  for pituitary cells was estimated to be 1.382,  $k$  is a factor related to cell distribution according to their size (in the case of GH cells its value is 1) and  $N_A$  is the number of cells in the plane of the pituitary tissue section.  $N_A$  is calculated as follows:

$$N_A = \Sigma N_n / \Sigma P_{tc} \cdot a,$$

where  $a$  represents the rhombic area belonging to every point of the test system and is calculated using the formula:

$$a = d^2 \cdot 3^{1/2} / 2$$

**Table 1.** Body weight, absolute and relative pituitary weights in sham-operated (SO), orchidectomized (Orx) and estradiol dipropionate (Orx+Edp) treated orchidectomized andropausal rats.

	SO	Orx	Orx+Edp
Body weight before the surgery (g)		680.0±30.0	
Body weight before the treatment (g)	654.0±8.0	639.0±63.0	639.0±63.0
Body weight after the treatment (g)	650.0±29.0	586.0 ±35.0 <sup>a</sup>	548.0±32.0 <sup>a</sup>
Absolute pituitary weight (mg)	17.0±1.7	16.6 ±1.4	42.5±8.0 <sup>a,b</sup>
Relative pituitary weight (mg/%)	2.2±0.1	2.5±0.2 <sup>a</sup>	7.8±0.6 <sup>a,b</sup>

Mean ± SD, n=8/group; <sup>a</sup>p<0.05 vs. SO rats, <sup>b</sup>p<0.05 vs. Orx rats

where  $d$  is the test line length in the test system employed.

Volume density ( $V_{VC}$ ) is calculated as the ratio of the sum of Pn and Ptc (Pn+Ptc) and the total number of points in the test system. Since the test system with 42 points was used and parameters were calculated using 50 test fields, the final formula was:

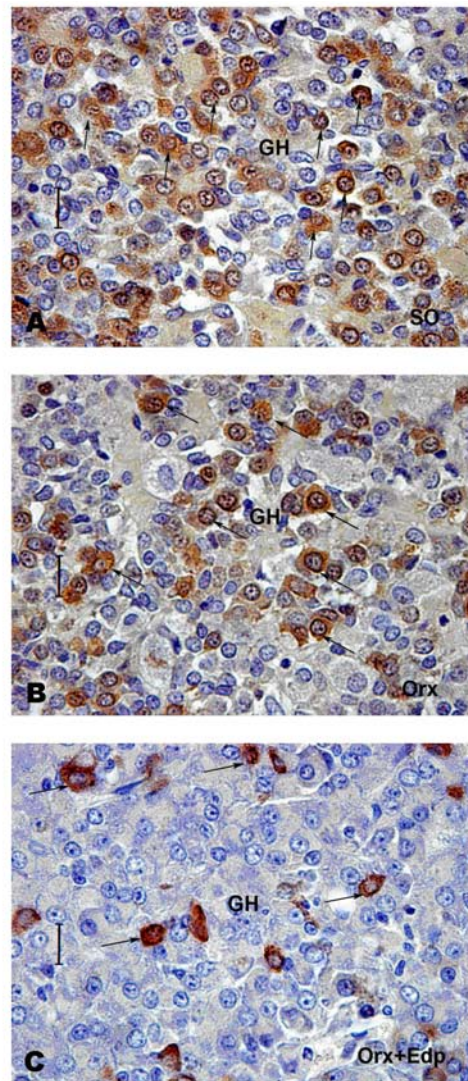
$$V_{VC} = (Pn+Ptc) / 50 \cdot 42$$

#### Statistical analyses

Morphometric data obtained for the experimental groups were subjected to one-way analyses of variance (ANOVA). Duncan's multiple range tests was used for *post hoc* comparisons between groups. A confidence level of  $p<0.05$  was considered statistically significant. The data are presented as means ± SD.

## RESULTS AND DISCUSSION

Data for the body weight, the absolute and relative pituitary weights in the andropausal rats are summarized in Table 1. The body weights in Orx and Orx+Edp rats were decreased ( $p<0.05$ ) by 10% and 16%, respectively, compared to the SO group. The absolute pituitary weight in the Orx+Edp animals was significantly increased ( $p<0.05$ ) in comparison with the SO and Orx animals, by 150% and 156%, respectively. The relative pituitary weight in the Orx+Edp group was also significantly increased ( $p<0.05$ ) by 254% and 212%, compared to the SO and Orx rats, respectively.



**Fig. 1.** Immunohistochemically labeled GH cells (marked with arrows) in: A) sham operated (SO) B) orchidectomized (Orx) and C) orchidectomized and estradiol dipropionate (Orx+Edp) treated andropausal rats (PAP; bar-16  $\mu$ m).

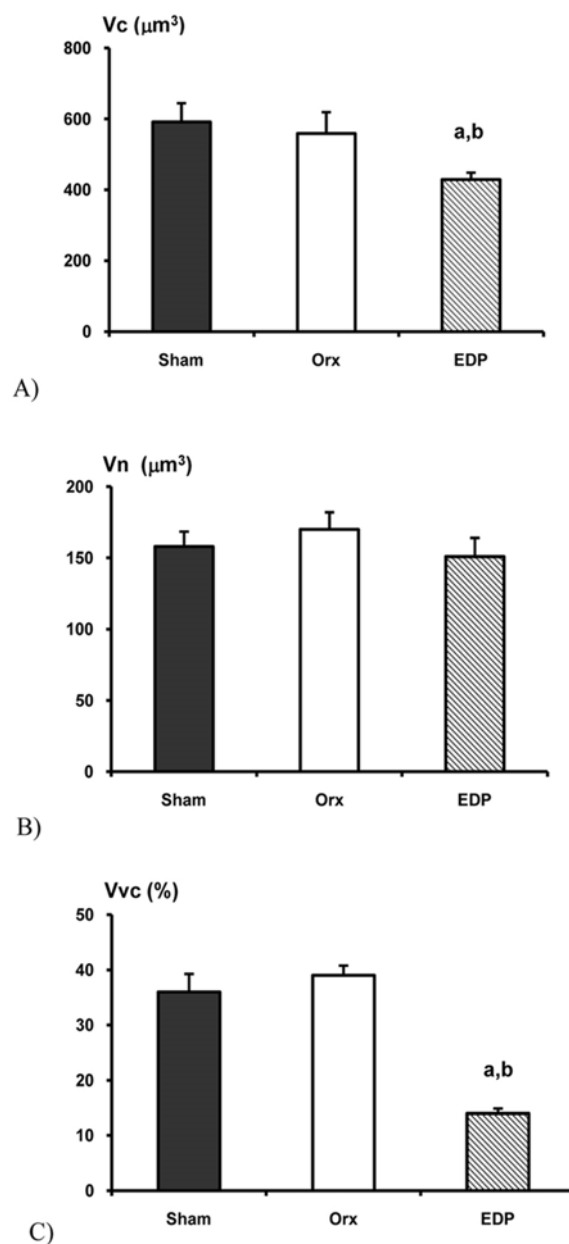


The more pronounced decrease in body weight was observed after the estradiol dipropionate treatment of orchidectomized animals. This led us to conclude that not only testosterone deprivation was responsible for the change. Namely, it was observed that estradiol induces hypophagia, associated with the increased hypothalamic expression of anorexigenic neuropeptides (Silva et al., 2010). In middle-aged female rats, chronic estradiol treatment was shown to increase absolute pituitary weight (Kostić et al., 2003). In addition, it has been demonstrated that estradiol treatment increases the number of chromophobes, PRL (Pantić 1980, 1995; Milošević et al., 2007) and LH cells (Lovren et al., 1997), which supports our results.

Immunohistochemically identified GH cells in **SO** and **Orx** rat pituitaries were ovoid to pyramidal in shape, with a spherical, centrally located nucleus. They were usually situated along the blood capillaries (Figs. 1A, 1B). In the **Orx+Edp** rats, the GH cells were smaller, irregularly shaped, with more intensely stained secretory granules (Fig. 1C), while the blood capillaries were dilated. Similar immunohistochemical findings were observed in middle-aged female rat pituitaries after treatment with estradiol (Milošević et al., 2005).

Morphometric studies revealed a significant decrease ( $p < 0.05$ ) in GH cell volumes and in relative volume densities (Figs. 2A, 2C) in the **Orx+Edp** rats, by 27.4% and 61.1%, respectively, compared to the respective parameters in the **SO** animals. The cell volumes and relative volume densities of GH cells in the **Orx+Edp** group were also significantly decreased ( $p < 0.05$ ), by 23.2% and 64.1% respectively, in comparison with the **Orx** animals. The nuclear volumes of GH cells were not significantly ( $p > 0.05$ ) changed in the **Orx+Edp** rats compared to both the **SO** and **Orx** groups (Fig. 2B).

As noted, andropause brings about certain changes at the level of GH cells. Estrogens are interesting because of their therapeutic use in some common ageing diseases. They generally assume relevant somatic roles. Several authors have reported



**Fig. 2.** A) Cell volume ( $V_c$ ;  $\mu\text{m}^3$ ), B) Nuclear volume ( $V_n$ ;  $\mu\text{m}^3$ ) and C) Relative volume density ( $V_{vc}$ ; %), expressed as percentages of total glandular tissue of immunopositive GH cells. The values are the means  $\pm$  SD, ( $n=8/\text{group}$ ); <sup>a</sup> $p < 0.05$  vs. **SO** rats, <sup>b</sup> $p < 0.05$  vs. **Orx** rats.

a decrease in the pituitary GH content with ageing in rats (Takahashi, 1992; Mobbs, 1996). The GH cell hormonal content decrease, observed in middle-aged rat females, was interpreted to be partly due to an increase in somatostatin release from hypothala-

mus (Takahashi et al., 1987). In adult and old rats, it was reported that GHRH and GHRH receptor genes were insensitive to androgens, so orchidectomy does not affect GHRH levels (De Gennaro Collona et al., 1991; Mayo et al., 2000). On the other hand, an earlier study demonstrated that estrogens reduce GHRH as well as GH secretion and lower pituitary responsiveness to GHRH stimulation (Pantić, 1980). Finally, estrogen directly inhibits the activity of the GHRH receptor gene promoter (Petersenn et al., 1998).

Based on the results presented here, it can be concluded that chronic estradiol dipropionate application in an animal model of the andropause results in the suppression of immunohistochemical and morphometric parameters of pituitary GH cells.

*Acknowledgment* - This work was supported by the Ministry for Education and Science of Republic of Serbia, Grant number 173009.

## REFERENCES

- Carani, C., Qin, K., Simoni, M., Faustini-Fustini, M., Serpente, S., Boyd, J., Korach, K.S., and E.R. Simpson (1997). Effect of testosterone and estradiol in a man with aromatase deficiency. *N. Engl. J. Med.* **337**, 91-95.
- Ceda, G.P., Dall'Aglio, E., Morganti, S., Denti, L., Maggio, M., Lauretani, F., Andrea, A., Cerasini, G., Cattabiani, C., and G. Valenti (2010). Update on new therapeutic options for the somatopause. *Acta Biomed.* **81**(Suppl.1), 67-72.
- De Gennaro Colonna, V., Cocchi, D., Lima, L., Maggi, A., and E.E. Müller (1991). Testosterone and GHRH gene expression in adult and old rats. *Peptides* **12**, 309-312.
- Di Somma, C., Brunelli, V., Savanelli, M.C., Scarano, E., Savastano, S., Lombardi, G., and A. Colao (2011). Somatopause: state of the art. *Minerva Endocrinol.* **36**, 243-255.
- Epelbaum, J. (2008). Neuroendocrinology and aging. *J. Neuroendocrinol.* **20**, 808-811.
- Grumbach, M.M., and R.J. Auchus (1999). Estrogen: consequences and implications of human mutations in synthesis and action. *J. Clin. Endocrinol. Metab.* **84**, 4677-4694.
- Kostić, N., Nestorović, N., Negić, N., and V. Milošević (2003). The effect of estradiol on the morphofunctional characteristics of ACTH cells in middle-aged rats. *Clinical Chemistry and Laboratory Medicine*, International Proceedings Division, 1137-1140.
- Lovren, M., Sekulić, M., Milošević, V., Mičić, M., and N. Radulović (1997). Alterations of pituitary immunohistochemical and morphometric parameters in juvenile female rats following estradiol and hCG treatment. *Jugoslav. Med. Biochem.* **16**, 83-88.
- Malendowicz, L.K. (1974). Sex differences in adrenocortical structure and function. I. The effects of postpubertal gonadectomy and gonadal hormone replacement on nuclear volume of adrenocortical cells in the rat. *Cell Tissue Res.* **151**, 525-536.
- Mayo, K.E., Miller, T., DeAlmeida, V., Godfrey, P., Zheng, J., and S.R. Cunha (2000). Regulation of the pituitary somatotroph cell by GHRH and its receptor. *Recent Prog. Horm. Res.* **55**, 237-267.
- Milošević, V., Brkić, B., Velkovski, S., and V. Starčević (1994). Somatostatin induced changes of the ACTH and STH cells in the hypophysis of the male rats. *Jugoslav. Med. Biochem.* **13**: 102-106.
- Milošević, V., Trifunović, S., Šošić-Jurjević, B., Bujšić, N., and M. Sekulić (2005). Estradiol and calcium affect the growth hormone-producing cells in middle-aged rat females. *Acta Vet.* **55**, 111-120.
- Milošević, V., Starčević, V., Šošić-Jurjević, B., Filipović, B., Trifunović, S., Ristić, N., Nestorović, N., Manojlović, M., and M. Sekulić (2007). Effect of estradiol or calcium treatment on mammothrophs of female middle-aged rats. *Acta Vet.* **57**, 393-402.
- Mobbs, C. (1996). Neuroendocrinology of aging. In: *Handbook of the Biology of Aging* (Eds. Schneider, E.L., Rowe, J.W.) 234-282, Academic Press, San Diego.
- Morales, A. (2004). Andropause (or symptomatic late-onset hypogonadism): facts, fiction and controversies. *Aging Male* **7**, 297-303.
- Pantić, V. (1980). Adenohypophyseal cell specificities and gonadal steroids In: *Synthesis and Release of Adenohypophyseal Hormones*. (Eds. Jutz, M., Mckerns, KW) 335-362, Plenum Press, New York.
- Pantić, V. (1995). Biology of hypothalamic neurons and pituitary cells. *Inter. Rev. Cytol.* **159**, 1-112.
- Petersenn, S., Rasch, A.C., Heyens, M., and H.M. Schulte (1998). Structure and regulation of the human growth hormone-releasing hormone receptor gene. *Mol. Endocrinol.* **12**, 233-247.
- Picherit, C., Coxam, V., Bennetau-Pelissero, C., Kati-Coulibaly, S., Davicco, M.J., Lebecque, P., and J.P. Barlet (2000). Daidzein is more efficient than genistein in preventing ovariectomy-induced bone loss in rats. *J. Nutr.* **130**, 1675-1681.
- Silva, L.E., Castro, M., Amaral, F.C., Antunes-Rodrigues, J., and L.L. Elias (2010). Estradiol-induced hypophagia is associ-

- ated with the differential mRNA expression of hypothalamic neuropeptides. *Braz. J. Med. Biol. Res.* **43**, 759-766.
- Sternberger, L.A., Hardy, P.H.J., Cuculius, J.J., and H.G. Meyer* (1970). The unlabelled antibody enzyme method of immunohistochemistry. Preparation and properties of soluble antigen-antibody complex (horseradish peroxidase-antihorseradish peroxidase) and its use in identification of spirochetes. *J. Histochem. Cytochem.* **18**, 315-333.
- Takahashi, S., and S. Kawashima* (1987). Proliferation of prolactin cells in rat: Effects of estrogen and bromocryptine. *Zool. Sci.* **4**, 855-860.
- Takahashi, S.* (1992). Heterogeneity and development of somatotropes and mammatropes in the rat. *Zool. Sci.* **9**, 901-924.
- Takahashi, S., Oomizu, S., and Y. Kobayashi* (1994). Proliferation of pituitary cells in streptozotocin-induced diabetic mice: effect of insulin and estrogen. *Zool. Sci.* **11**, 445-449.
- Tamella, T.* (2004). Endocrine treatment of prostate cancer. *J. Steroid Biochem. Mol. Biol.* **92**, 287-295.
- Thompson, C.A., Shanafelt, T.D., and C.L. Loprinzi* (2003). Andropause: Symptom management for prostate cancer patients treated with hormonal ablation. *The Oncologist* **8**, 474-487.
- Vance, M. L.* (2003). Andropause. *Growth Horm. IGF Res.* **13** (Suppl.A), S90-92.
- Weibel, E.R.* (1979) Stereological methods. 1. *Practical methods for biological morphometry.* 1-415. Academic Press, New York.

