

## BASIC INDICES OF SPLEEN IMMUNE ACTIVITY IN NATURAL POPULATIONS OF NORWAY RATS (*RATTUS NORVEGICUS* BERKENHOUT, 1769) IN SERBIA

MILENA KATARANOVSKI<sup>1,2</sup>, IVANA MIRKOV<sup>1</sup>, LIDIJA ZOLOTAREVSKI<sup>3</sup>,  
ALEKSANDRA POPOV<sup>1</sup>, SANDRA BELIJ<sup>1</sup>, JELENA STOŠIĆ<sup>1</sup>, and D. KATARANOVSKI<sup>1,4</sup>

<sup>1</sup>Department of Ecology, Siniša Stanković Institute for Biological Research, University of Belgrade, 11060 Belgrade, Serbia

<sup>2</sup>Institute of Physiology and Biochemistry, Faculty of Biology, University of Belgrade, 11000 Belgrade, Serbia

<sup>3</sup>Institute of Pathology, Military Medical Academy, 11000 Belgrade, Serbia

<sup>4</sup>Institute of Zoology, Faculty of Biology, University of Belgrade, 11000 Belgrade, Serbia

**Abstract** — Basic parameters of spleen immune activity (spleen weight, histomorphology of splenic compartments, and mitogen-induced splenocyte proliferative capacity *in vitro*) were evaluated in adult individuals of wild Norway rats from urban habitats and compared to the same data obtained in laboratory rat strains. A wider range of relative spleen mass and differential histomorphological characteristics, together with differences in the level and pattern of responsiveness of splenocytes to exogenous stimulation, were noted in spleens of wild Norway rats. Evidence of both enhanced and low-level immune-relevant spleen activity in wild rats demonstrates the complexity of changes in spleen immune activity in rats from natural populations.

**Key words:** Wild Norway rats, spleen immune activity, Serbia

UDC 599.323.4:612.017

### INTRODUCTION

The vertebrate immune system is suited to combat or control microbial infection and to restore tissue homeostasis. In this way, it contributes to the general physiological condition of an organism. Owing to such great importance, many studies have been devoted to evaluation of the immunity in wild animals (Lochmiller and Deerenberg, 2000; Zuk and Stoehr, 2002). It is difficult to investigate the state of immune system function in natural populations because intrinsic factors such as genetic background, sex, and age introduce intraspecies variation (Zuk and Stoehr, 2002). Assessment of the ability to mount immune defense against pathogens (immunocompetence) (Owens and Wilson, 1999; Adamo, 2004), determination of peripheral blood leukocyte counts (Wolk and Kozłowski, 1989; Robel et al., 1996; Weber et al., 2002), and estimation of immune responsiveness to experimental challenge with non-pathogenic substances (Zuk and Stoehr, 2002; Gouy de Belocq et al., 2006, 2007a) are the most frequently

used approaches in evaluating the state of immune system function in wild animals. It is also possible to analyze immune responsiveness to *in vivo* or *in vitro* immune challenge in laboratory-raised wild-caught animals (McMurry et al., 1995; Klein et al., 1997). Another approach is simultaneous examination of Norway rats from natural habitats and individuals of laboratory Norway rat strains that had been raised shielded from a variety of environmental stimuli (Devalapalli et al., 2006).

While white blood cell counts are an indirect measure of host immune system function, the ability to respond to pathogens or non-pathogenic substances is a direct measure of host immune status. In wildlife studies, immunocompetence is often assessed by ascertaining spleen size (Grassman, 2002) and by measuring *in vitro* splenocyte responsiveness to non-microbial substances such as plant lectins (Klein et al., 1997). Recent advances in knowledge of spleen structure and function (Mebius and Kraal, 2005) and use of the rodent spleen in

pathological studies (Cesta, 2006) have brought new insights into the importance of this organ in wildlife studies. While knowledge of rat spleen structure and immune-relevant function is substantial and widely employed in fundamental physiological research (Haley, 2003), characteristics of the immune activity of this lymphoid organ in Norway rats from natural populations are largely unknown.

The aim of this study was to obtain data on basic immune-relevant activity of the spleen in Norway rats from natural populations. Easily measured parameters of spleen immune activity (relative weight, histomorphological characteristics of splenic compartments, and plant lectin-induced splenocyte proliferative capacity *in vitro*) were determined. The intestinal helminth burden was assessed as a factor shown to be relevant for spleen size in some rodent species (Gouy de Belocq et al., 2007b). Individuals of the same age classes and of both sexes were analyzed in an attempt to reduce variations due to the effect of internal factors. To lessen variations influenced by external (environmental) factors, rats caught in ecologically similar habitats and during the same seasons were included in the study. Measurements were conducted comparatively in age- and sex-matched individuals of several laboratory strains of Norway rats shielded from environmental influences in order to gain some insight into the effect of the environment on natural populations of Norway rats. The obtained data indicate both enhanced and suppressed spleen immune activity, implying complexity of changes in the spleen of rats from natural populations.

## MATERIALS AND METHODS

### *Animal collection*

Rats were captured with live traps in the urban area of Belgrade, Serbia (44°N, 20°E, the approximate geometric center of Belgrade lying at 44°49'14"N, 20°27'44"E) from March to September of 2005 and 2006. They were housed in wire-mesh cages at the animal facility of the Siniša Stanković Institute for Biological Research in Belgrade for one week in order from them to adapt to captivity. Only rats with good body condition and apparent health were included

in the study. Pregnant and lactating females, as well as animals with signs of injuries, were not used. Individuals of the Wistar, Albino Oxford, and Dark Agouti rat lines from the aforementioned animal facility were used for comparative evaluations. Rats were fed commercial rodent feed and had access to water *ad libitum*.

### *Necropsy procedures*

Anesthetized (sodium thiopental, Rotexmedica, Tritau, Germany) animals were euthanized by cervical dislocation following spleen harvesting. Body weight measurements were taken with a balance (+/- 0.1 g). Spleens were removed, cleaned of fat and extraneous tissue, blotted dry, and wet masses weighed using a precision balance (+/- 0.01 g). The relative spleen mass was calculated according to the following formula: organ mass/body mass x 100.

### *Helminth collection*

The stomach, small intestine, cecum and colon were separated, opened longitudinally, and their contents rinsed out with a 0.85% NaCl solution. The livers were examined for the presence of metacestodes. Helminthic parasites were recovered alive, counted, and identified under a stereoscopic microscope according to descriptions given by Genov (1984).

### *Spleen histology*

Spleen pieces were cut out and immediately fixed in 4% formalin (pH 6.9). After processing, tissue was embedded in paraffin wax for sectioning at 5 µm. Hematoxylin and eosin (H&E)-stained histology slides were subsequently analyzed by light microscopy.

### *Spleen cell counts*

Spleen cells were obtained aseptically by gentle teasing of spleen tissue through stainless steel mesh and suspended in Roswell Park Memorial Institute (RPMI)-1640 cell culture medium (Flow, ICN Pharmaceuticals, Costa Mesa, USA) supplemented with 2 mM glutamine, 5x10<sup>-5</sup> M 2-mercaptoethanol, 60 µg/ml gentamycin, and 5% (v/v) heat-inactivated fetal calf serum (complete medium). Splenocyte counts were made using an improved Neubauer

hemocytometer chamber. Cell viability as determined by trypan blue exclusion exceeded 95%.

#### *Spleen cell proliferation*

The functional status of splenocytes was determined by their capacity to proliferate in response to stimulation by the T-cell mitogenic lectin concanavalin-A (Con-A, Pharmacia, Uppsalla, Sweden). Proliferation was evaluated using a colorimetric assay based on the tetrazolium salt 3-(4, 5-dimethyl-2-thiazolyl)-2, 5-diphenyl-2H-tetrazolium bromide (MTT) as described elsewhere (Berridge et al., 1996). Cells were adjusted to  $3 \times 10^6$  cells by dilution with complete culture medium and then added in triplicates to wells of sterile 96-well microculture plates ( $0.3 \times 10^6$  cells/well). Serial two-fold concentrations of ConA (1.25 to 20  $\mu\text{g/ml}$ ) or only medium were added to the culture wells. Plates were incubated at 37°C with an atmosphere of 5%  $\text{CO}_2$  for two days prior to addition of MTT (10  $\mu\text{L}$ , 5 mg/ml), and incubation was continued for an additional 3 h. The formazan product formed during MTT reduction was solubilized with an acidified sodium dodecyl sulfate solution (10% SDS-0.01N HCl) and optical density (OD) measured with a microplate spectrophotometer (GRD, Rome, Italy) at 540 nm. The proliferative response was expressed as the optical density (OD) generated by Con-A-stimulated splenocytes, based on the enzymatic reaction that correlates with the amount of cell division (Klein et al., 1997). Mean OD values for each set of triplicates were used in statistical analyses.

#### *Data display and analysis*

Results are expressed as means  $\pm$  SD with range (min-max) values. Statistical analysis was performed using the STATISTICA 7.0 statistical software package (StatSoft Inc., Tulsa, Oklahoma, USA). Significance was defined by the Mann-Witney U-test and by two-sided difference tests. We considered *P*-values less than 0.05 to be significant.

## RESULTS

#### *General animal population data*

Of the captured rats, 20 male and 28 female adults, as determined by the dry eye lens weight method

(Kataranovski et al., 1994), were included in this study. Both young and older adults weighing from 200 to 443 g (males) and from 162 to 430 g (females) were used. Age-matched laboratory animals (27 males and 21 females) were used in the study, and their weights ranged from 200 to 435 g (males) and from 150 to 310 g (females).

#### *Spleen mass*

A very wide range of relative spleen mass values was noted in wild-caught rats (Table 1). High relative spleen mass ( $0.49 \pm 0.24$ ,  $n = 5$  in males and  $0.5 \pm 0.19$ ,  $n = 15$  in females) vs. published values of approximately 0.2 in various laboratory rat strains) were responsible for the higher upper value within the spleen mass to body mass ratio range in wild animals vs. laboratory rats.

As a link between spleen size and response to multicellular helminth endoparasites was noted in some rodent species, the presence of these parasites was screened in wild Norway rats. Only eight animals were without parasites (three males and five females). The rest of the animals harbored five nematode (*Heterakis spumosa*, *Nippostrongylus brasiliensis*, *Aspicularis tetraptera*, *Syphacia muris*, and *Syphacia* spp.) and three cestode (*Hymenolepis diminuta*, *Rodentolepis nana*, and *Taenia taeniaeformis* larvae) species. No correlation was noted between the logarithms of total helminth infection intensity, nematode infection intensity, or cestode infection intensity and spleen size (correlation coefficient  $r = 0.02-0.277$ ,  $p > 0.154$  for all).

#### *Spleen histological morphology*

Histological examination of spleens revealed a difference in the ratio of white pulp to red pulp between wild and laboratory rats (Fig. 1). Similar proportions (approximately 50% to 50%) of the two spleen zones were noted in the majority of wild rats, both males and females. Lower (40%) and higher (60 and 70%) proportions of white pulp were noted in some female wild rats. In contrast, a greater proportion of white pulp, around 70% relative to red pulp was noted in more than 80% of laboratory rats.

Histological examination of the marginal zone, the region between the interface of red pulp and

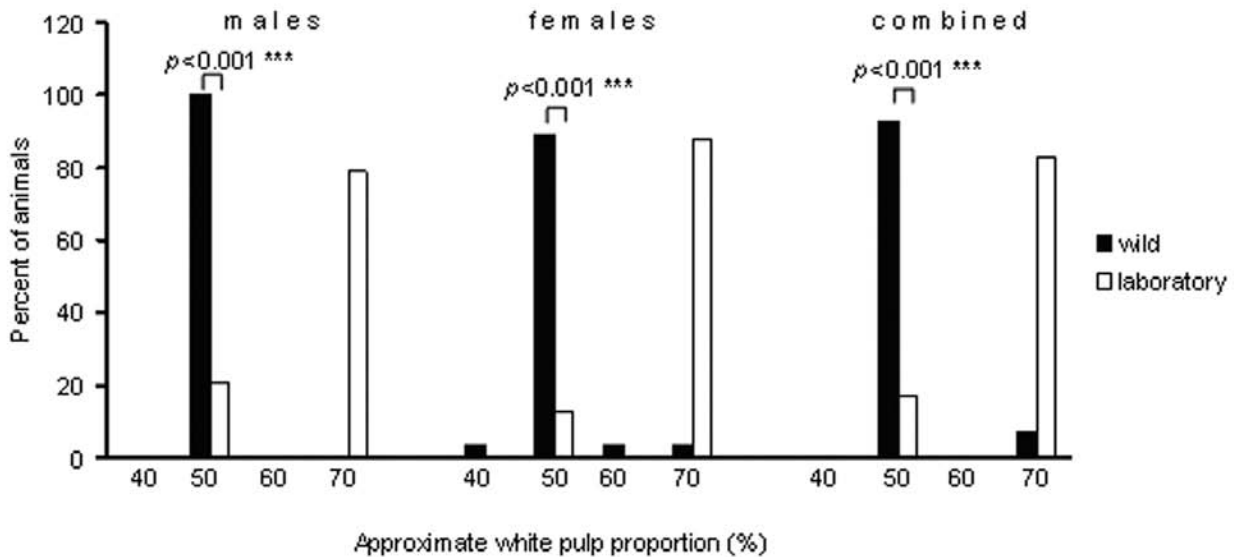


Fig. 1. Prevalence of white pulp in spleen of wild and laboratory Norway rats.

white pulp (Cesta, 2006), revealed heterogeneity of marginal zone (MZ) appearance in wild rats, ranging from poorly demarcated to clearly distinct (Fig. 2). Dissimilarity of the prevalence of marginal zones with different appearance was noted between spleens of wild and laboratory animals (Fig. 3). Greater prevalence of a less distinct marginal zone (2+) and lower prevalence of a more distinct (3+) marginal zone were noted in wild rats compared to laboratory rats, with higher percentages of MZ scores of 2+ and 3+ in spleens of males and females, respectively. In some wild female rats a marginal zone with low distinction (1+) was noted, while no such poorly developed MZ was detected in laboratory animals. Negligible numbers of wild rats had a well expressed (4+) marginal zone.

Lymphoid follicles were variable in size, ranging from poorly developed (+/-) to well developed (3+) in rats from both natural and laboratory populations. However, atrophic germinal centers were detected in some wild rats (Fig. 4). The presence of follicles with an indistinct germinal center was also noted in wild Norway rats. No follicles with such germinal center appearance were noted in laboratory animals.

#### *Proliferative response of spleen cells to ConA stimulation*

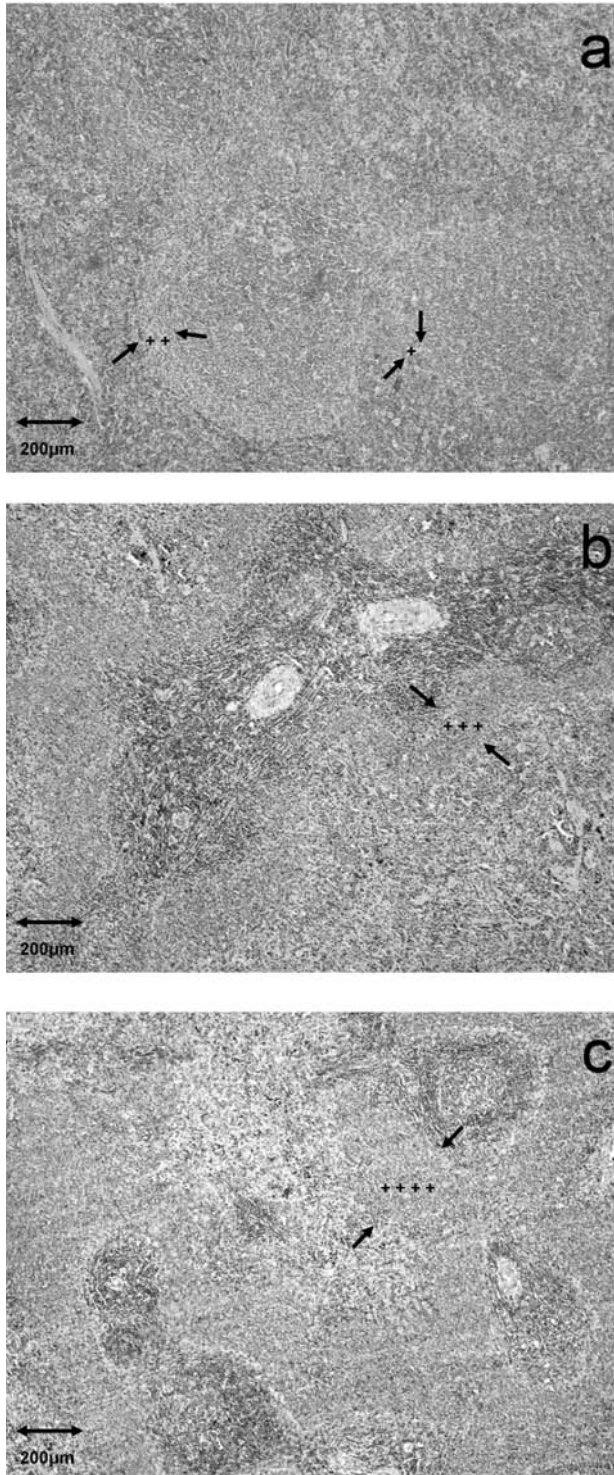
Stimulation of spleen cells with various doses of ConA (1.25 to 20 µg/ml) revealed differences both in

the level and in the pattern of the response between wild and laboratory rats. Doses of 1.25-10 µg ConA/ml resulted in statistically significant increase of proliferation with a maximum at 10 µg ConA/ml in splenocytes of wild male rats (Fig. 5a). Low doses (1.25-2.5 µg ConA/ml) significantly stimulated proliferation of spleen cells of male laboratory rats, with a peak of proliferation at 2.5 µg ConA/ml in male laboratory rats. In contrast, insignificantly increased low levels of proliferation were noted in wild-caught female rats at all mitogen doses used, while a wide range of ConA doses resulted in increased proliferation of splenocytes in female individuals of laboratory rats (Fig. 5b).

## DISCUSSION

In this study, basic indices of immune-relevant activity of the spleen (spleen mass, histological morphology of the spleen, and the capacity of spleen cells to proliferate in response to exogenous stimulation) were determined in Norway rats from natural populations and compared to the same in laboratory rats.

As the largest secondary lymphoid organ in the body, the spleen is involved in the capture and destruction of pathogens and the induction of immune responses. The ratio of splenic mass to body



**Fig. 2.** Appearance marginal zone in spleen of wild rats. (a) Indistinct (1+) and poorly distinct (2+) marginal zones. (b) More distinct (3+) marginal zone. (c) Well expressed (4+) marginal zone.

mass is fairly constant in laboratory rats and is typically around 0.2 (Cesta, 2006). Higher relative spleen mass in wild compared to laboratory Norway rats might reflect greater engagement of the spleen in rats from natural populations in immune defense against environmental microbes. Experimental rodent studies demonstrated the spleen's importance in defense against blood-borne pathogens, including bacteria and viruses (Mebius and Kraal, 2005). Although we did not determine bacterial or viral loads in wild rats, other observations demonstrated the presence of various parasites, including viruses, bacteria, protozoa, and ectoparasites, apart from gastrointestinal helminths (Sunbul et al., 2001; Battersby et al., 2002; Easterbrook et al., 2007) in rats from urban habitats. In the light of these data, larger relative spleen masses in wild rats might be envisaged as an organism's investment in immunity against a wide range of environmental microbes. The noted sexual differences of relative spleen weight (heavier spleens in wild female rats) are in line with data indicating heavier spleens in female birds (Moeller et al., 1998) and boars (Fernandez-Liario et al., 2004) from natural populations. The observed sexual differences might be ascribed to the influence of sex hormones, since rats were captured during the period of reproductive activity for these animals (Hrgović et al., 1991).

The lack of correlation between spleen mass and infection with helminths noted in our study is in line with data indicating the absence of a link between these parameters in wild-derived mouse strains (Gouy de Bellocq et al., 2007b). Despite data pointing to a link between spleen size and helminth load in some vertebrate species, including fishes (Lefebvre et al., 2004), birds (Shutler et al., 1999; Morand and Poulin, 2000), and shrews (Gouy de Bellocq et al., 2007b), and the spleen's importance in acting against experimental nematode infection in laboratory mice (Ali and Behnke, 1985; John, 1994), the question of the relationship between spleen size and helminth load is a controversial issue. Data suggesting that spleen enlargement reflects the host's inability to manipulate neurotropic nematodes in rats (Horak et al., 2006), the negative correlation between spleen mass and lung nematode infection in deer from

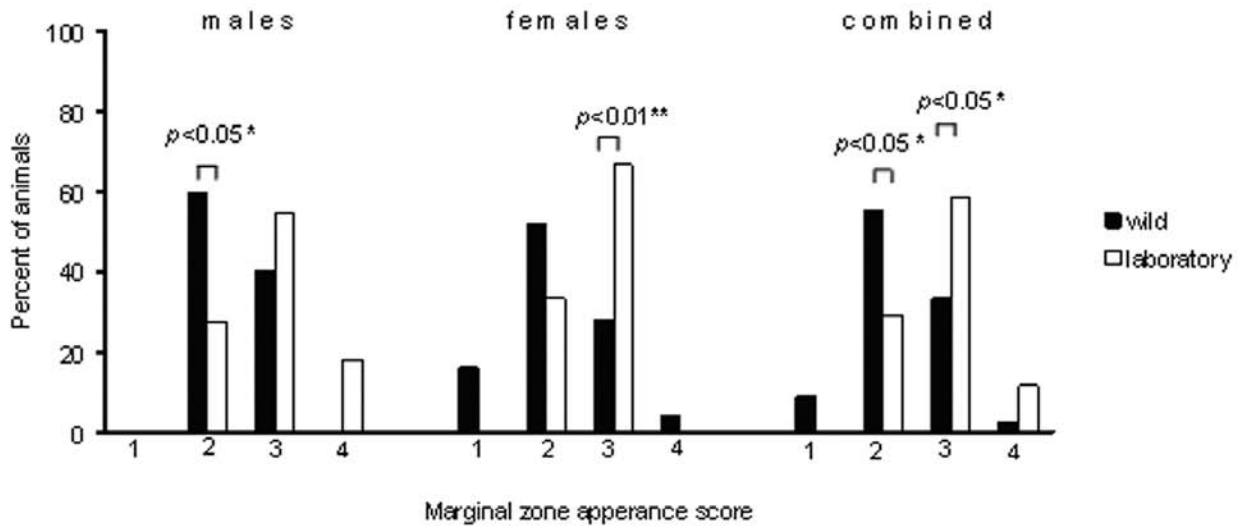


Fig. 3. Prevalence of marginal zones with different appearance in spleen of wild and laboratory Norway rats.

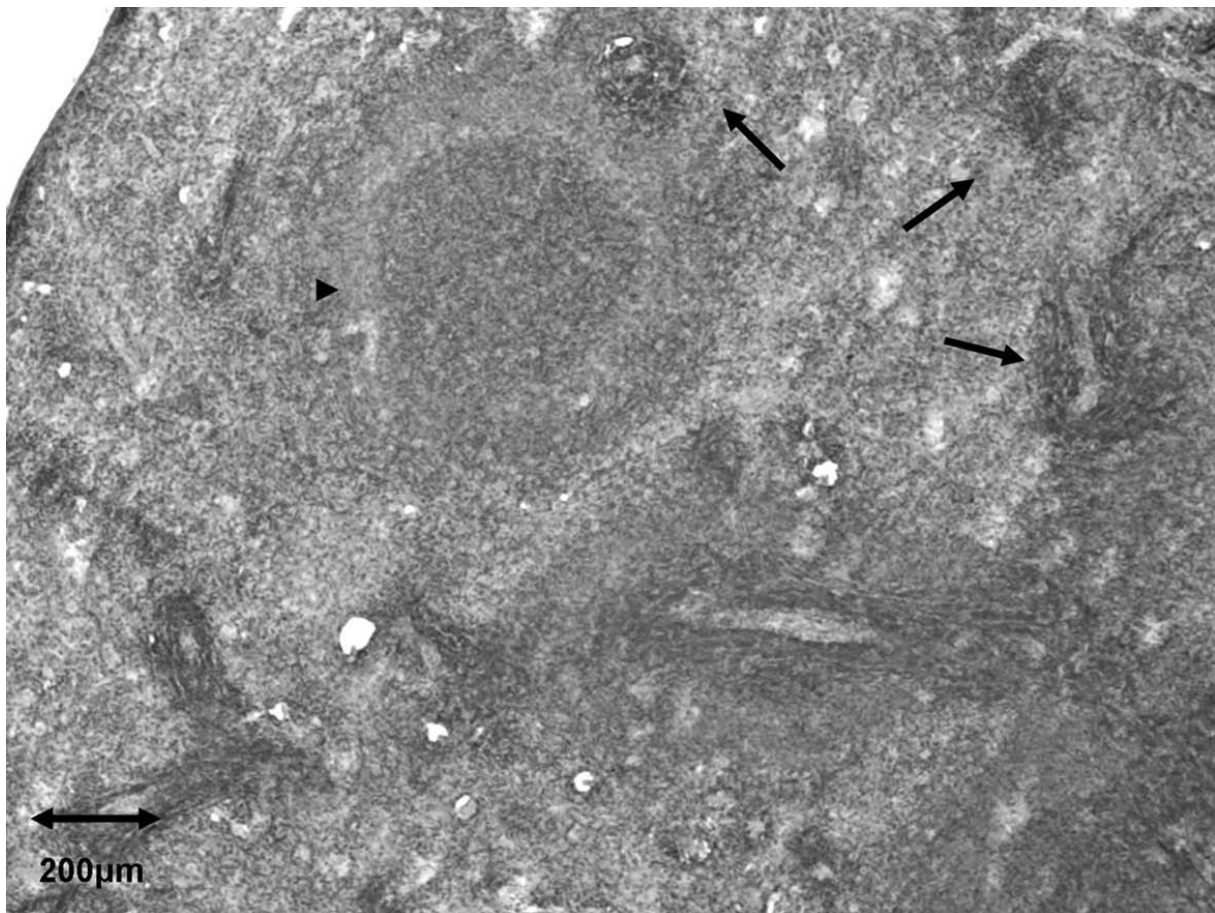
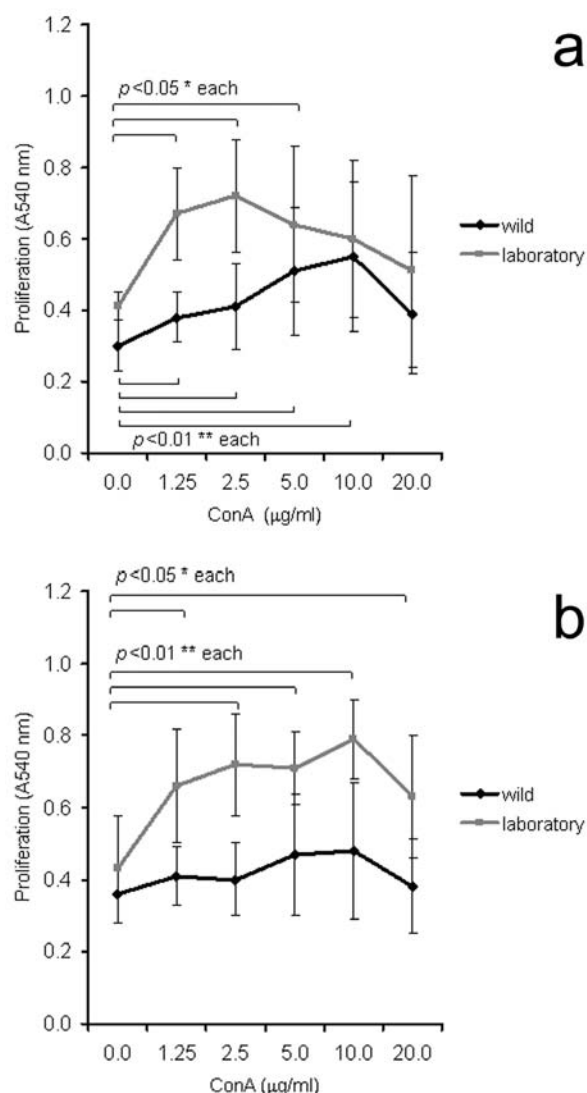


Fig. 4. Different grades of lymphoid follicle atrophy in wild rat. Atrophic follicles (arrows). Follicle with indistinct germinal center (arrowhead).



**Fig. 5.** Proliferative response of spleen cells from wild and laboratory Norway rats to ConA stimulation. Data are represented as means of absorbance units measured in cell cultures of spleens from wild or laboratory animals. (a) males, (b) females.

natural populations (Vicente et al., 2007), and the lack of correlation between resistance to intestinal helminth parasites and spleen mass in laboratory mice (Gouy de Bellocq et al., 2007a) argue against such a relationship, showing that this issue is very difficult to resolve in mammals.

The spleen accommodates phagocytosis and iron storage, besides inducing immune responses.

The given functions are combined through compartmentalization of the spleen into different regions with adaptations (Mebius and Kraal, 2005). These microanatomically distinct regions are the white pulp (lymphoid region of spleen), red pulp (area of blood filtering and iron recycling), and the space between them, the marginal zone. The similar proportions of white and red pulp (50%: 50%) revealed by histomorphological analysis in the majority of wild rats, compared to the greater proportion (70%) of white pulp in laboratory rats, might have resulted from increased red pulp activities, including blood filtering, iron metabolism, and removal of bacteria from the blood by red pulp macrophages in wild rats. Red pulp is also a site of hematopoiesis in rodents (Mebius and Kraal, 2005; Cesta, 2006), and the increased proportion of this region in wild rats might have resulted from the need for synthesis of new blood cells in these animals. White pulp is the lymphoid region of the spleen involved in adaptive (specific) immunity, in which cells of the immune system migrate and lodge in the various compartments within this area. The smaller proportion of white pulp in wild-caught rats compared to laboratory rats might indicate somewhat lower lymphoid activity in this area. The presence of varying degrees of lymphoid follicle atrophy (depressed white pulp) supports such a possibility. The appearance of atrophic lymphoid follicles might have resulted from strong, exhaustive immune activity in this region, as was shown in laboratory mice after *i.v.* injection of microbial antigens (Mirkov et al., 2008).

The marginal zone is histologically prominent in rats compared to other rodents (MacLennan et al., 1982). This unique region is an important transit area for cells leaving the blood stream and entering white pulp. Functionally, the marginal zone is designed to screen systemic circulation for pathogens and contains cells involved in both innate (nonspecific) and adaptive (specific) immunity to these antigens (Mebius and Kraal, 2005; Cesta, 2006). Increased prevalence of a less distinct and lower prevalence of a more distinct marginal zone in wild rats indicates differences in the integrity of this region between wild and laboratory rats. Differences in interactions between migratory and resident cells

of spleen regions, on whose maintenance of marginal zone integrity relies (Mebius and Kraal, 2005) can be envisaged, a possibility that warrants future attention.

The response of spleen cells to ConA is a reliable marker of rodent immune system function, as is observed in various rodent species (Hart, 1978; Lee et al., 2005). The low proliferative response to ConA observed in wild Norway rats might have resulted from a heavy parasite load, as shown in laboratory mice (Sciutto et al., 1995). Extensive parasitism is present in wild Norway rats from urban populations (Battersby et al., 2002; Easterbrook et al., 2007), which can result in generally increased immune stimulation in these animals (Devalalalli et al., 2006). Such a response is often accompanied by a robust counteracting anti-inflammatory regulatory network (Leshner et al., 2006), which might be the underlying mechanism of low splenocyte responsiveness to exogenous ConA stimulation in wild rats.

Besides parasitism, other environmental influences such as chemical stressors (McMurry et al., 1999) might contribute to the relative insensitivity of spleen cells from wild rats to exogenous stimulation. In this connection, variability of the spleen's ConA response was noted in individuals with increased spleen mass among wild cotton rats (*Sigmodon hispidus*) inhabiting contaminated sites (McMurry et al., 1999).

In conclusion, the data obtained in this study demonstrate differences in several basic spleen immune activity indices between Norway rats from natural and laboratory populations. Evidence of both enhanced and low-level immune-relevant spleen activity in wild vs. laboratory rats, demonstrates the complexity of changes in spleen immune activity in rats from natural populations. The presented data represent an initial source of baseline information concerning the status of spleen immune activity in Norway rats from natural populations. Such information can be useful for further studies with these animals.

*Acknowledgments* — This study was supported by the Ministry of Science and Technological Development of the Republic of Serbia (Grant # 143038). Animal treatment was carried out in

adherence with standards set by the Ethical Committee of the Siniša Stanković Institute for Biological Research. The authors would like to thank Olivera Vukičević-Radić for helminth determination and Dušica Radović for technical assistance in some aspects of the investigation.

## REFERENCES

- Adamo, S. A. (2004). How should behavioral ecologists interpret measurements of immunity? *Anim. Behav.* **68**, 1443-1449.
- Ali, N. M., and J. M. Behnke (1985). Observations on the gross changes in the secondary lymphoid organs of mice infected with *Nematospiroides dubius*. *J. Helminthol.* **59**, 167-174.
- Battersby, S. A., Parsons, R., and J. P. Webster (2002). Urban rat infestations and the risk to public health. *J. Environ. Health Res.* **1**, 4-12.
- Berridge, M. V., Tan, A. S., McCoy, K. D., and R. R. Wang (1996). The biochemical and cellular basis of cell proliferation assay that use tetrazolium salts. *Biochemica* **4**, 15-20.
- Gouy de Bellocq, J., Krasnov, B. R., Khokhlova, I. S., and B. Pinshow (2006). Temporal dynamics of a T-cell mediated immune response in desert rodents. *Comp. Biochem. Physiol. Mol. Integr. Physiol.* **145**, 554-559.
- Gouy de Bellocq, J., Porcherie, A., Moulia, C., and S. Morand (2007a). Immunocompetence does not correlate with resistance to helminth parasites in house mouse subspecies and their hybrids. *Parasitol. Res.* **100**, 321-328.
- Gouy de Bellocq, J., Ribas, A., Casanova, J. C., and S. Morand (2007b). Immunocompetence and helminth community of the white-toothed shrew, *Crocidura russula*, from the Montseny Natural Park, Spain. *Eur. J. Wildl. Res.* **53**, 315-320.
- Cesta, M. F. (2006). Normal structure, function, and histology of the spleen. *Toxicol. Pathol.* **34**, 455-465.
- Devalapalli, A., Leshner, A., Shieh, K., Everett, M. L., Edala, A. S., Whitt, P., Long, R. R., Newton, N., and W. Parker (2006). Increased levels of IgE and autoreactive, polyreactive IgG in wild rodents: implications for the hygiene hypothesis. *Scand. J. Immunol.* **64**, 125-136.
- Easterbrook, J. D., Kaplan, J. B., Vanasco, N. B., Reeves, W. K., Purcell, R. H., Kosoy, M. Y., Glass, G. E., Watson, J., and S. L. Klein (2007). A survey of zoonotic pathogens carried by Norway rat in Baltimore, Maryland, USA. *Epidemiol. Infect.* **135**, 1192-1199.
- Fernandez-Liario, P., Parra, A., Cerrato, R., and J. Hermoso De Mendosa (2004). Spleen size variations and reproduction in a Mediterranean population of wild boar (*Sus scrofa*). *Eur. J. Wildl. Res.* **50**, 13-17.
- Genov, T. (1984). *Helminths of Insectivorous Mammals and Rodents in Bulgaria*, 348 pp. Bulg. Acad. Sci., Sofia.
- Grassman, K. A. (2002). Assessing immunological function in



- toxicological studies of avian wildlife. *Integr. Comp. Biol.* **42**, 34-42.
- Haley, P. J. (2003). Species differences in the structure and function of the immune system. *Toxicology* **188**, 49-71.
- Hart, D. A. (1978). Effect of zinc chloride on hamster lymphoid cells: mitogenicity and differential enhancement of lipopolysaccharide stimulation of lymphocytes. *Infect. Immun.* **19**, 457-461.
- Horak, P., Tummeleht, L., and H. Talvik (2006). Predictors and markers of resistance to neurotropic nematode infection in rodent hosts. *Parasitol. Res.* **98**, 396-402.
- Hrgović, N., Vukićević, O., and D. Kataranovski (1991). Basic biological characteristics of pest rodents. In: *Deratization: Pest Rodent Control* (Ed. S. Jovanović), 11-28. Dečje Novine, Gornji Milanovac.
- John, J. L. (1994). Nematodes and the spleen: an immunological relationship. *Cell. Mol. Life Sci.* **50** (Suppl. 1), 15-22.
- Kataranovski, D., Kataranovski, M., Savić, I. R., Soldatović, B., and R. Matić (1994). Morphometric and biochemical parameters as age indicators in the Norway rat (*Rattus norvegicus* Berk., 1769). *Acta Vet.* **44**, 371-378.
- Klein, S. L., Hairston, J. E., Devries, C. A., and R. J. Nelson (1997). Social environment and steroid hormones affect species and sex differences in immune function among voles. *Horm. Behav.* **32**, 30-39.
- Lee, J. K., Ryu, M. H., and J. A. Byun (2005). Immunotoxic effect of beta-chlorolactic acid on murine splenocyte and peritoneal macrophage function *in vitro*. *Toxicology* **210**, 175-178.
- Lefebvre, F., Mounaix, B., Poizat, G., and A. J. Crivelli (2004). Impacts of the swimbladder nematode *Anguillicola crassus* on *Anguilla anguilla*: variations in liver and spleen masses. *J. Fish Biol.* **64**, 435-447.
- Leshner, A., Li, B., Whitt, P., Newton, N., Devalapalli, A., Shieh, K., Solow, J. S., and W. Parker (2006). Increased IL-4 production and attenuated proliferative and pro-inflammatory responses of splenocytes from wild-caught rats (*Rattus norvegicus*). *Immunol. Cell Biol.* **84**, 374-382.
- Lochmiller, R., and C. Deerenberg (2000). Trade-offs in evolutionary immunology: just what is the cost of immunity? *Oikos* **88**, 87-98.
- MacLennan, I. C. M., Gray, D., Kumararatne, D. S., and H. Bazin (1982). The lymphocytes of the marginal zone: a distinct B cell lineage. *Immunol. Today* **3**, 305-307.
- McMurry, S. T., Lochmiller, R. L., Chandra, S. A. M., and C. W. Qualls Jr. (1995). Sensitivity of selected immunological, hematological, and reproductive parameters in the cotton rat (*Sigmodon hispidus*) to subchronic lead exposure. *J. Wildl. Dis.* **31**, 193-204.
- McMurry, S. T., Lochmiller, R.L., McBee, K., and C. W. Qualls Jr. (1999). Indicators of immunotoxicity in populations of cotton rats (*Sigmodon hispidus*) inhabiting an abandoned oil refinery. *Ecotoxicol. Environ. Saf.* **42**, 223-235.
- Mebius, R. E., and G. Kraal (2005). Structure and function of the spleen. *Nat. Rev. Immunol.* **5**, 606-616.
- Mirkov, I., Zolotarevski, L., Glamočlija, J., Kataranovski, D., and M. Kataranovski (2008). Experimental disseminated aspergillosis in mice: histopathological study. *J. Myc. Med.* **18**, 75-82.
- Moeller, A. P., Sorci, G., and J. Erritzoe (1998). Sexual dimorphism in immune defense. *Am. Nat.* **152**, 605-619.
- Morand, S., and R. Poulin (2000). Nematode parasite species richness and the evolution of spleen in birds. *Can. J. Zool.* **78**, 1356-1360.
- Owens, I. P. F., and K. Wilson (1999). Immunocompetence: a neglected life history trait or conspicuous red herring? *Trends Ecol. Evol.* **14**, 170-172.
- Robel, G. L., Lochmiller, L., McMurry, S. T., and C. W. Qualls (1996). Environmental, age, and sex effects on cotton rat (*Sigmodon hispidus*) hematology. *J. Wildl. Dis.* **32**, 390-394.
- Sciutto, E., Fragoso, G., Baca, M., De La Cruz, V., Lemus, L., and E. Lamoyi (1995). Depressed T-cell proliferation associated with the susceptibility to experimental *Taenia crassiceps* infection. *Infect. Immun.* **63**, 2277-2281.
- Shutler, D., Alisauskas, R. T., and J. D. McLaughlin (1999). Mass dynamics of the spleen and other organs in geese: measures of immune relationship to helminths? *Can. J. Zool.* **77**, 351-359.
- Sunbul, M., Esen, S., Leblebicioglu, H., Hokelek, M., Pekbay, A., and C. Eroglu (2001). *Rattus norvegicus* acting as reservoir of *Leptospira interrogans* in the Middle Black Sea region of Turkey, as evidenced by PCR and presence of serum antibodies to *Leptospira* strain. *Scand. J. Infect. Dis.* **33**, 896-898.
- Vicente, J., Perez-Rodriguez, L., and C. Gortazar (2007). Sex, age, spleen size, and kidney fat of red deer relative to infection intensities of the lungworm *Elaphostrongylus cervi*. *Naturwissenschaften* **94**, 581-587.
- Weber, D. K., Danielson, K., Wright, S., and J. E. Foley (2002). Hematology and serum biochemistry values of dusky-footed wood rat (*Neotoma fuscipes*). *J. Wildl. Dis.* **38**, 576-582.
- Wolk, E., and J. Kozłowski (1989). Changes in body weight and hematological parameters in fluctuating population of *Apodemus flavicollis*. *Acta Theriol.* **34**, 439-464.
- Zuk, M., and A. M. Stoehr (2002). Immune defense and host life history. *Am. Nat.* **160** (Suppl.), S9-S22.

## ПАРАМЕТРИ ИМУНСКЕ АКТИВНОСТИ У СЛЕЗИНИ КОД ЈЕДИНКИ СИВОГ ПАЦОВА ИЗ ПРИРОДНИХ ПОПУЛАЦИЈА (*RATTUS NORVEGICUS BERKENHOUT, 1769*) ИЗ СРБИЈЕ

МИЛЕНА КАТАРАНОВСКИ<sup>1,2</sup>, ИВАНА МИРКОВ<sup>1</sup>, ЛИДИЈА ЗОЛОТАРЕВСКИ<sup>3</sup>,  
АЛЕКСАНДРА ПОПОВ<sup>1</sup>, САНДРА БЕЛИЈ<sup>1</sup>, ЈЕЛЕНА СТОШИЋ<sup>1</sup> и Д. КАТАРАНОВСКИ<sup>1,4</sup>

<sup>1</sup>Одељење за екологију, Институт за биолошка истраживања “Синиша Станковић”, Универзитет у Београду,  
11060 Београд, Србија

<sup>2</sup>Институт за физиологију и биохемију, Биолошки факултет, Универзитет у Београду, 11000 Београд, Србија

<sup>3</sup>Институт за патологију, Војно-медицинска академија, 11000 Београд, Србија

<sup>4</sup>Институт за зоологију, Биолошки факултет, Универзитет у Београду, 11000 Београд, Србија

Испитивани су основни параметри имунске активности у слезини (маса слезине, хистоморфологија и способност ћелија слезине да пролиферишу у одговору на митоген у *in vitro* условима) код адултних јединки сивога пацова из урбаних станишта и поређени са подацима добијеним код лабораторијских сојева пацова. Код јединки из природних попу-

лација је запажен већи опсег релативних маса слезине, различите хистоморфолошке карактеристике и разлике у нивоу и начину одговора ћелија слезине на егзогену стимулацију у поређењу са јединкама лабораторијских сојева. Ови подаци указују на комплексне промене у имунској активности слезине код јединки из природних популација.