

COMBINED TREATMENT WITH RIBAVIRIN AND TIAZOFURIN ATTENUATES RESPONSE OF GLIAL CELLS IN EXPERIMENTAL AUTOIMMUNE ENCEPHALOMYELITIS

DANIJELA SAVIĆ¹, IRENA LAVRNJA¹, SANJA DACIĆ², IVANA BJELOBABA¹,
NADEŽDA NEDELJKOVIĆ², SANJA PEKOVIĆ¹ and MIRJANA STOJILJKOVIĆ¹

¹ Department for Neurobiology, Institute for Biological Research "Siniša Stanković", University of Belgrade, 11000 Belgrade, Serbia

² Institute for Physiology and Biochemistry, Faculty of Biology, University of Belgrade, 11000 Belgrade, Serbia

Abstract - Experimental autoimmune encephalomyelitis (EAE) is an animal model of multiple sclerosis (MS), a human inflammatory and demyelinating disease. Microglia and astrocytes are glial cells of the central nervous system (CNS) that play a dual role in MS and EAE pathology. The aim of this study was to examine the effect of combined treatment with two nucleoside analogues, ribavirin and tiazofurin, on microglia and astrocytes in actively induced EAE. Therapeutic treatment with a combination of these two nucleoside analogues reduced disease severity, mononuclear cell infiltration and demyelination. The obtained histological results indicate that ribavirin and tiazofurin changed activated microglia into an inactive type and attenuated astrocyte reactivity at the end of the treatment period. Since reduction of reactive microgliosis and astrogliosis correlated with EAE suppression, the present study also suggests that the obtained beneficial effect of ribavirin and tiazofurin could be a consequence of their action inside as well as outside the CNS.

Key words: Experimental autoimmune encephalomyelitis, glial cells, ribavirin, tiazofurin

INTRODUCTION

Multiple sclerosis (MS) is a chronic demyelinating inflammatory disease of the human central nervous system (CNS) characterized by a variable degree of axonal loss that correlates with neurological disability (Bjartmar et al., 2000). Experimental autoimmune encephalomyelitis (EAE) is an animal model of multiple sclerosis (MS) and a helpful tool in the preclinical testing of various substances under consideration for treatment of this human disease of the CNS.

Ribavirin (RBV; 1- β -D-ribofuranosyl-1,2,4-triazole-3-carbox-amide) and tiazofurin (TR; 2- β -D-ribofuranosylthiasole-4-carboxamide) are synthetic nucleoside analogues that exert immunosuppressive action in EAE (Stosic-Grujicic et al., 2002; Lavrnja et

al., 2008; Stojkov et al., 2008) through the inhibition of inosine-monophosphate-dehydrogenase (IMP-DH), a rate-limiting enzyme in the *de novo* purine synthesis pathway.

A normal mature nervous system possesses resident immunocompetent cells, known as microglia. They persist as a resting ramified form that upon even minor disturbances in the CNS, become activated amoeboid cells. Once activated, microglia produce various proinflammatory factors (i.e. TNF- α , IL-1 β , IL-6) (Smith et al., 2012), which alert nearby astroglial cells and trigger astrogliosis (Glass et al., 2010). Reactive astrogliosis can play a detrimental role in MS and EAE, since reactive astrocytes may act as proinflammatory mediators (Nair et al., 2008). In addition, it has been shown that increased glial

scarring, as a consequence of chronic disease activity in MS, is associated with an accumulating neurological deficit (Raine, 1997).

Since our prior experiments were focused on the peripheral effects of RBV and TR in EAE, the present study addressed the question as to whether CNS cells, microglia and astrocytes could be the potential targets in a RBV+TR combined therapy, administered at the appearance of the first clinical signs of EAE. We carried out clinical, histopathological and immunohistochemical evaluations of EAE to reveal the effect of this drug cocktail on glial cells.

MATERIALS AND METHODS

Animals and EAE induction

Male Dark Agouti (DA) rats (12 weeks old), were obtained from the Institute for Biological Research "Siniša Stanković" (Belgrade, Serbia). Three to five animals (200-250 g) were kept per cage. The rats were immunized as previously described in Stojkov et al. (2008). Animals were monitored daily for the clinical signs EAE which were scored from 0 to 5 using the following scale: (0) no clinical signs; (1) flaccid tail; (2) hind limb paresis; (3) hind limb paralysis; (4) moribund state, (5) death. The following parameters of the disease were examined to evaluate the severity of EAE during the treatment period (15 days): mean clinical score (average clinical scores for all rats within a group on a given treatment day); mean maximal severity score (the mean of the maximal clinical score that each rat in a group developed over the treatment period); duration of paralysis (the mean number of days during the treatment period for which the rats had a score of 3 or more). All animals were treated in accordance with the principles from the Guide for Care and Use of Laboratory Animals, NIH Publication No. 80-23 and the protocols were approved by the Belgrade University Animal Care and Use Committee.

Treatment procedure

Ribavirin (RBV) and tiazofurin (TR) were provided

by ICN Pharmaceuticals (Costa Mesa, CA, USA). The rats were randomly divided at the beginning of the experiment into 2 groups: an EAE group (saline treated, 0.2 ml/kg/day of saline *i.p.*) and a RBV+TR group which was treated with a combination of the following dosages: 30 mg/kg/day (RBV) + 10 mg/kg/every other day (TR). In all groups, each animal was treated individually, beginning from the appearance of the first signs of EAE (from 7 to 11 days post immunization). The treatment period lasted for 15 days. After cessation of treatment, the animals were killed under deep anesthesia, from day 21 to day 25, depending on the onset of the disease for each animal. The spinal cords were dissected and prepared for cryosectioning.

Histochemistry and immunohistochemistry

Frozen transverse 16 µm-thick lumbar spinal cord sections were used for histological and immunological analysis. Histological staining with Luxol Fast Blue (LFB)/Cresyl Violet (CV) was performed to detect demyelination and inflammatory infiltrates according to standard procedure. Immunolabeling was performed for anti-ED1 (Serotec, mouse, 1:400), anti-GFAP (DAKO, rabbit, 1:500) and anti-vimentin (DAKO, mouse, 1:200). Briefly, non-specific binding was reduced with 10% normal goat serum (for ED1 and vimentin) or 10% normal rabbit serum (for GFAP) in 0.01 M phosphate buffered saline pH 7.4. Primary antibodies were applied overnight at 4°C. Appropriate horseradish peroxidase conjugated secondary antibodies (Santa Cruz Biotechnology, Santa Cruz, CA, USA) were used and the reaction product was visualized with 3'3-diaminobenzidine (DAB, Dako) according to the manufacturer's instructions. Negative control of labeling was performed by the omission of the primary antibody, and did not result in specific labeling. After dehydration and clearing, sections were mounted with DPX Mounting medium (Fluka) and examined under a Zeiss Axiovert microscope.

Statistical Analysis

The results are expressed as means ± SEM. Signifi-

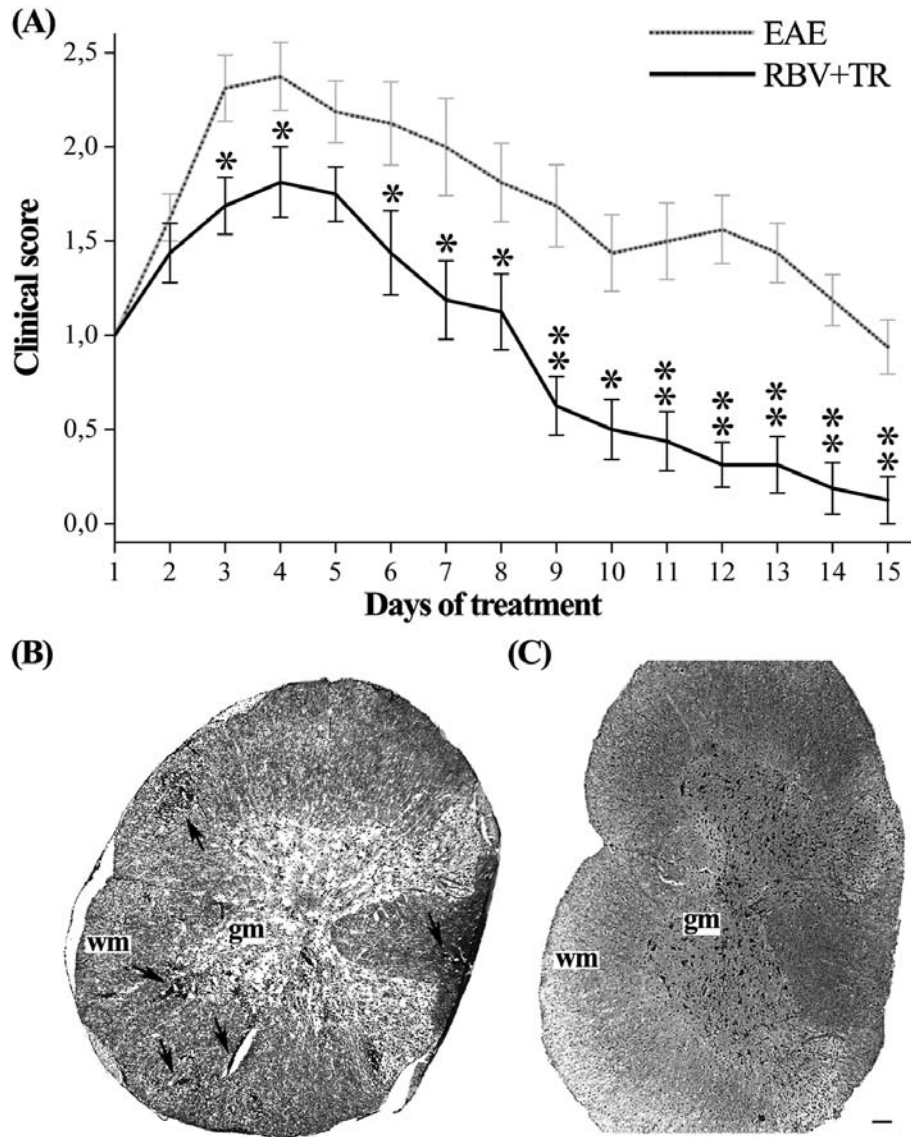


Fig. 1. Clinical and pathological features of EAE. (A) The effect of RBV+TR treatment on the suppression of clinical signs of EAE over the treatment period (15 days). Results are means \pm SEM. * $P < 0.05$, ** $P < 0.001$ vs. EAE-rats that were used as controls. Detection of demyelination and inflammatory infiltrates in 16- μ m-thick cryosections of the lumbar spinal cord by Luxol Fast Blue/Cresyl Violet staining in EAE rats (B, arrows) and RBV+TR treated rats (C). Gray matter (gm) and white matter (wm). Bar B-C: 100 μ m.

cance between the differences of the disease parameters: mean clinical score, mean maximal severity score and duration of paralysis, were evaluated by ANOVA. Significant differences were accepted at * $P < 0.05$ and ** $P < 0.001$ vs. EAE-rats that were used as controls.

RESULTS

Clinical and general pathological features of EAE rats treated with RBV+TR

All immunized animals developed clinical signs of

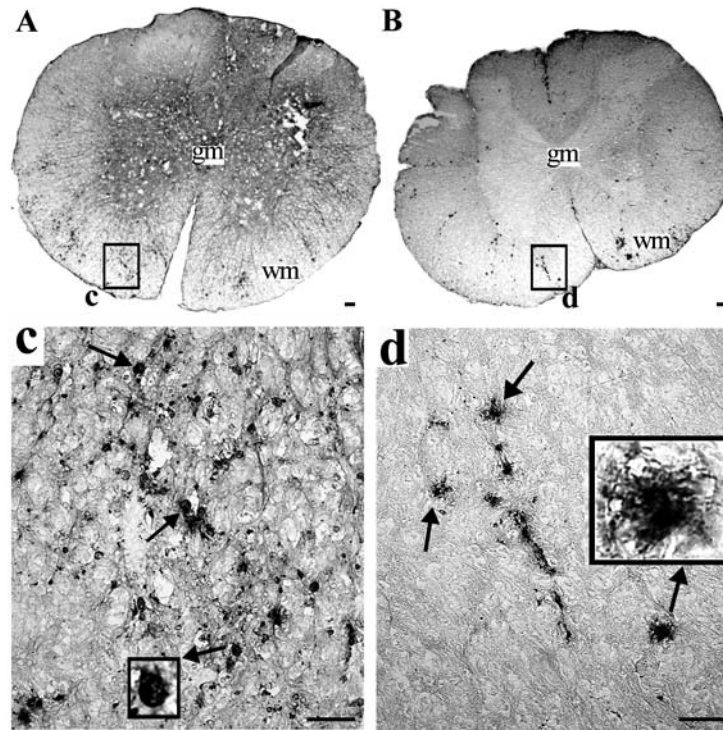


Fig. 2. ED1 immunostaining of lumbar spinal cord sections of EAE- and RBV+TR- animals. (A) In EAE rats, a huge number of microglial cells with a morphology similar to macrophages (c, arrows, insert) were seen. In RBV+TR-treated rats a paucity of bushy microglial cells resembling resting microglia were noticed (B, d, arrows, insert). Gray matter (gm) and white matter (wm). Bars A, B: 400 μ m; c, d: 100 μ m.

disease. In order to ensure that RBV+TR treatment was initiated at the beginning of the disease, the treatment was applied individually, at the appearance of the first sign of EAE (flaccid tail), and lasted 15 days. RBV+TR-treated rats developed a noticeably milder form of EAE (Fig. 1A), as judged by several parameters of disease severity (Table 1). In the RBV+TR-group, only 5 of 16 animals passed through paralysis, while 14 out of 16 animals from the EAE-group had this severe disease symptom. On cessation of treatment, 15 out of 16 RBV+TR-treated rats completely recovered, and one animal exhibited paresis. In EAE-untreated animals, at the end of treatment protocol, only 3 out of 16 rats completely recovered, 11 rats had flaccid tails and 2 displayed paresis. In addition, mortality was not registered in any of the groups.

LFB/CV staining of lumbar spinal cord sections revealed widespread demyelination that correlated

with massive cellular infiltrates throughout the white matter columns and gray matter of EAE-rats (Fig. 1B, arrows). In the RBV+TR-treated rats, demyelination plaques were not detected and the white matter, as well as the gray matter of these rats was devoid of cellular infiltrates (Fig. 1C).

The effect of the combined treatment with RBV+TR on microglial activation in EAE rats

An ED1 microglial marker was used to evaluate microglia reactivity in the EAE-untreated and RBV+TR-treated rats. In the EAE-rats microglial cells were retracted and exhibited an amoeboid shape throughout the white matter of the lumbar spinal cord, suggestive of a macrophage-like cell type (Fig. 2A and c, insert). In the RBV+TR-treated rats, microglia exhibited a bushy morphology with short and thick processes (Fig. 2B and d, insert),

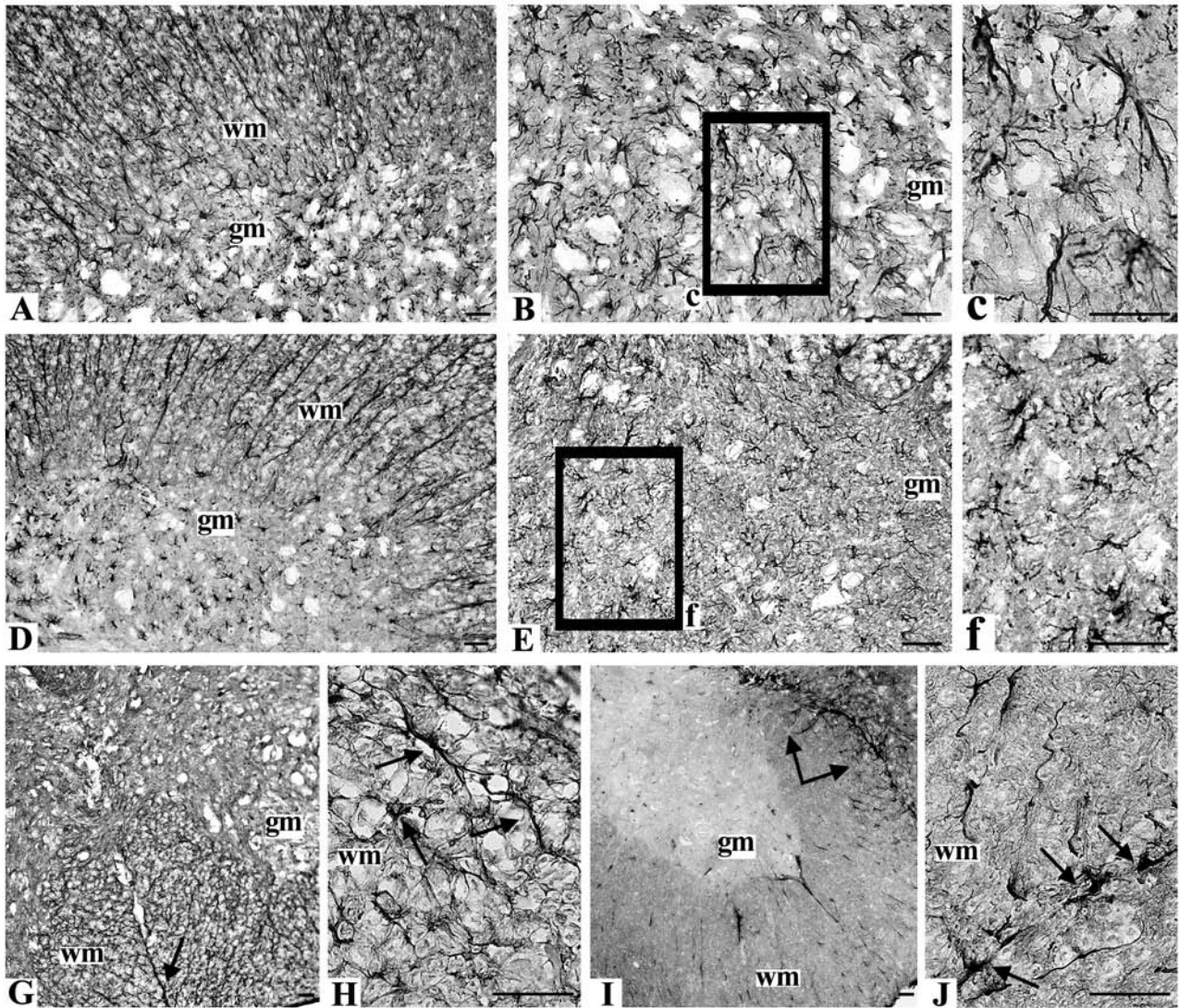


Fig. 3. GFAP and Vimentin immunostaining of lumbar spinal cord sections of EAE- and RBV+TR- animals. GFAP⁺ astrocytes of similar morphology were spread throughout the white matter of EAE rats (A) and RBV+TR-rats (D). In the gray matter of EAE-rats strong GFAP immunoreactivity was noticed, indicating astrocyte activation (B, c), whereas in RBV+TR-treated rats normal astroglial cells with small cell bodies and thin processes were observed (E, f). Vimentin⁺ astrocytes in EAE-rats formed a dense mesh of vimentin⁺ elongated astrocytes with small cell bodies and thin processes (G, H, arrows). In the white matter of RBV+TR-treated rats, vimentin immunoreactivity was minimal (I), except in the close vicinity of the perivascular space in the ventral columns of the white matter where vimentin⁺ astrocytes were clustered around the blood vessels (I, J, arrows). Bars A-J: 50 μ m.

displaying a less activated state compared to the amoeboid microglia in the EAE rats. Quantitative studies of the microglial cell reactivity in the lumbar spinal cord of both groups of animals are presented in Table 2.

The effect of the combined treatment with RBV+TR on astroglial reactions in EAE rats

We used glial fibrillary acidic protein (GFAP) and vimentin to determine astrocyte reactivity after 15

Table 1. The effect of RBV+TR treatment on the parameters of disease severity.

	EAE	RBV+TR
№ of animals	16	16
mean clinical score per treatment day	1.68 ± 0.12	0.93 ± 0.17**
Mean maximal severity score	2.88 ± 0.10	2.13 ± 0.18**
Duration of paralysis	2.50 ± 0.43	0.50 ± 0.22**

Parameters of disease severity were evaluated as described in Materials and methods. Data are presented as mean ± SEM. * $P < 0.05$; ** $P < 0.001$ vs. EAE-rats that were used as controls.

Table 2. Degree of immunoreactivity for microglial cells (ED1), mature (GFAP) and immature (Vimentin) astrocytes in the EAE- and RBV+TR-groups

Lumbar region of spinal cord	Groups	ED1	GFAP	Vimentin
white matter	EAE	+++	++	+++
	RBV+TR	+	++	+
gray matter	EAE	++	+++	+
	RBV+TR	0	+	+

(0 = none, + minimal, ++ moderate, and +++ strong reactivity). Results are based on evaluation of lumbar spinal cord region of 3 – 4 animals per group.

days of treatment in the white and gray matter of the lumbar spinal cord sections of the EAE-untreated and RBV+TR-treated rats. In the white matter of both groups, we detected the same level of GFAP immunoreactivity (Fig. 3A and D, Table 2). In the gray matter of the EAE rats, increased GFAP immunoreactivity characterized by astrocytes with swollen cell bodies and thick processes was seen (Fig. 3B and c, Table 2). Conversely, in the gray matter of the RBV+TR-treated rats a reduction of GFAP immunoreactivity was observed; these astrocytes had small cell bodies and thin processes (Fig. 3E and f, Table 2).

In addition, vimentin immunohistochemistry of the lumbar spinal cord sections demonstrated minimal and moderate reactivity in the gray matter of the RBV+TR-treated and EAE-rats, respectively (Table 2). Analysis of vimentin staining in the white matter of the EAE-rats revealed a strong immunoreactivity and a dense mesh of vimentin⁺ astrocytes that were elongated, with small cell bodies and thin processes (Fig. 3G and H, Table 2). Conversely, vimentin immunoreactivity in the white matter of the RBV+TR-treated rats was minimal (Table 2), except in the close vicinity of perivascular space in the ventral columns

of white matter where an increased number of vimentin⁺ astrocytes was detected (Fig. 3I and J).

DISCUSSION

In this study we have shown that combined treatment with ribavirin (RBV) and tiazofurin (TR) reduced the number and modulated the morphology of glial cells in established EAE in DA rats. Namely, combined treatment of EAE animals with RBV+TR switched the morphology of activated microglia into a less activated phenotype and suppressed reactive astrogliosis at the end of the treatment period.

Since previously we confirmed that the co-administration of RBV and TR has a more potent effect in attenuating the clinical signs of EAE than each drug given individually (Stojkov et al., 2006), in this study we used a combined therapeutic approach as well. Consistent with our prior findings (Stojkov et al., 2008), combined RBV+TR treatment significantly suppressed the development of EAE in terms of reducing disease severity, mononuclear cell infiltration and demyelination. Considering that both of these nucleoside analogues could readily pass BBB (Colombo et al., 2011; Janac et al.,

2004), in this study we addressed the question of the impact of RBV and TR on the CNS and glial cells in particular. Microglial cells are crucial for the progress of MS and EAE since the activated form acquires the functional and morphological features of macrophages (Raivich and Banati, 2004). Activated microglia have the task of alerting nearby cells to possible threat and to provide for neuronal survival. On the other hand, during the chronic neuroinflammation that is a hallmark of MS and EAE, prolonged or excessive activation of microglial cells occurs and induces a potentially neurotoxic effect (Block et al., 2007). Thus, the prevalence of activated round-shaped macrophage-like microglial cells that we detected in the vicinity of the demyelinating areas in EAE animals can be considered as detrimental. Conversely, the less activated intermediate type of microglia that we observed in the RBV+TR-treated animals may have a beneficial role.

Activated microglial cells interact with another glial cell type, astrocytes, and trigger the process of reactive astrogliosis (Glass et al., 2010). MS lesions are characterized by an accumulation of hypertrophic reactive astroglia that show strong GFAP, nestin and vimentin immunoreactivity (Voskuhl et al., 2009), similar to those observed in this study. Existing data indicate a dual role of astrocytes in MS and EAE development. Thus, reactive astrocytes have in some cases been proposed as potential mediators in the effector phase of EAE (Girvin et al., 2002) and as a source of proinflammatory cytokines (Nair et al., 2008). On the other hand, the loss of scar-forming reactive astrocytes or interruption of their barrier functions may exacerbate the CNS pathology occurring in diseases like MS and EAE (Voskuhl et al., 2009). In the present study, the gray matter astroglia of EAE animals showed prominent hypertrophy and was correlated with massive peripheral cell infiltration. Wu et al. (2008) reported pronounced gray matter astrocyte activation in the presence of apoptotic oligodendrocyte processes in chronic EAE. In addition, neuronal death and gray matter atrophy was documented in mice with EAE (MacKenzie-Graham et al., 2006). Therefore, suppression of gray matter astrogliosis by RBV+TR treatment could indicate a

reduction in neuronal or oligodendrocyte apoptosis. Astrogliosis is also characterized by the rapid synthesis of two other intermediate filaments (vimentin and/or nestin) (Williams et al., 2007). Vimentin-bearing astrocytes of the adult CNS have a mixed composition of cytoskeletal intermediate filaments that are positive for both GFAP and vimentin (Oblinger et al., 1993). Therefore, the attained stronger immunoreactivity to vimentin in the white matter of EAE animals compared to RBV+TR-treated animals was expected. However, it appears that combination therapy did not affect vimentin-positive astrogliosis adjacent to the perivascular space in the ventral columns of white matter. This selective action of combination therapy could be beneficial since it was shown that reactive astrocytes might form scar-like perivascular barriers that limit the influx of immune and inflammatory leukocytes into CNS parenchyma (Voskuhl et al., 2009).

The possible mechanism of RBV and TR action on activated glial cells could be via the inhibition of IMPDH, the rate-limiting enzyme of *de novo* GTP biosynthesis. Through the inhibition of IMPDH II isoform, they exert antiproliferative action on rapidly dividing cells (Weber, 2005). Since this pathway is essential for normal, as well as mitogenic functions of all cells, inhibition of IMPDH II probably represents the main mechanism of RBV and TR deactivation and antiproliferative actions on activated microglia and reactive astrogliosis.

To summarize, although it is well documented that RBV and TR suppress EAE acting outside the CNS (Stosic-Grujicic et al., 2002; Lavrnja et al., 2008; Stojkov et al., 2008), the results presented in this study clearly indicate that RBV and TR could be neuroprotective through the modulation of glial cell response during EAE. Therefore, the combined administration of RBV and TR could be a promising therapeutic option against neurological disorders aggravated by excessive microglial activation and reactive astrogliosis.

Acknowledgments - This work was supported by the Serbian Ministry of Education and Science, Project No: III41014.

REFERENCES

- Bjartmar, C., Kidd, G., Mörk, S., Rudick, R., and B.D. Trapp (2000). Neurological disability correlates with spinal cord axonal loss and reduced N-acetyl aspartate in chronic multiple sclerosis patients. *Ann. Neurol.* **48**, 893-901.
- Block, M.L., Zecca, L., and J.S. Hong (2007). Microglia-mediated neurotoxicity: uncovering the molecular mechanisms. *Nature reviews. Neurosci.* **8**, 57-69.
- Colombo, G., Lorenzini, L., Zironi, E., Galligioni, V., Sonvico, F., Balducci, A.G., Pagliuca, G., Giuliani, A., Calzà, L., and A. Scagliarini (2011). Brain distribution of ribavirin after intranasal administration. *Antiviral Res.* **92**, 408-414.
- Girvin, A.M., Gordon, K.B., Welsh, C.J., Clipstone, N.A., and S.D. Miller (2002). Differential abilities of central nervous system resident endothelial cells and astrocytes to serve as inducible antigen-presenting cells. *Blood* **99**, 3692-3701.
- Glass, C.K., Saijo, K., Winner, B., Marchetto, M.C., and F.H. Gage (2010). Mechanisms underlying inflammation in neurodegeneration. *Cell* **140**, 918-934.
- Janac, B., Pesic, V., Veskov, R., Ristic, S., Tasic, J., Piperski, V., Ruzdijic, S., Jokanovic, M., Stukalov, P., and Lj. Rakic (2004). The effects of tiazofurin on basal and amphetamine-induced motor activity in rats. *Pharmacol. Biochem. Behav.* **77**, 575-582.
- Lavrnja, I., Stojkov, D., Bjelobaba, I., Pekovic, S., Dacic, S., Nedeljkovic, N., Mostarica-Stojkovic, M., Stosic-Grujicic, S., Rakic, L., and M. Stojiljkovic (2008). Ribavirin ameliorates experimental autoimmune encephalomyelitis in rats and modulates cytokine production. *Int. Immunopharmacol.* **8**, 1282-1290.
- MacKenzie-Graham, A., Tinsley, M.R., Shah, K.P., Aguilar, C., Strickland, L.V., Boline, J., Martin, M., Morales, L., Shattuck, D.W., Jacobs, R.E., Voskuhl, R.R., and A.W. Toga (2006). Cerebellar cortical atrophy in experimental autoimmune encephalomyelitis. *Neuroimage* **32**, 1016-1023.
- Nair, A., Frederick, T.J., and S.D. Miller (2008). Astrocytes in multiple sclerosis: a product of their environment. *Cell Mol. Life Sci.* **65**, 2702-2720.
- Oblinger, M.M., and L.D. Singh (1993). Reactive astrocytes in neonate brain upregulate intermediate filament gene expression in response to axonal injury. *Int. J. Dev. Neurosci.* **11**(2):149-56.
- Raine, C.S. (1997). The neuropathology of multiple sclerosis. *Multiple Sclerosis: Clinical and Pathogenetic Basis* (Eds. C.S. Raine, H.F. McFarland, and W.W. Tourtellotte), 243-286. Chapman & Hall, London.
- Raivich, G., and R. Banati (2004). Brain microglia and blood-derived macrophages: molecular profiles and functional roles in multiple sclerosis and animal models of autoimmune demyelinating disease. *Brain Res. Brain Res. Rev.* **46**, 261-81.
- Smith, J.A., Das, A., Ray, S.K., and N.L. Banik (2012). Role of pro-inflammatory cytokines released from microglia in neurodegenerative diseases. *Brain Res. Bull.* **87**, 0-20.
- Stojkov, D., Lavrnja, I., Pekovic, S., Dacic, S., Bjelobaba, I., Mostarica-Stojkovic, M., Stosic-Grujicic, S., Nedeljkovic, N., Rakic, L., and M. Stojiljkovic (2008). Therapeutic effects of combined treatment with ribavirin and tiazofurin on experimental autoimmune encephalomyelitis development: clinical and histopathological evaluation. *J. Neurol. Sci.* **267**, 76-85.
- Stojkov, D., Lavrnja, I., Subasic, S., Bjelobaba, I., Pekovic, S., Gadjanski, I., Mostarica-Stojkovic, M., Stosic-Grujicic, S., Rakic, L., and M. Stojiljkovic (2006). Therapeutic effects of nucleoside analogues on experimental autoimmune encephalomyelitis in Dark Agouti rats. *Arch. Biol. Sci.* **58**, 13-20.
- Stosic-Grujicic, S., Savic-Radojevic, A., Maksimovic-Ivanic, D., Markovic, M., Bumbasirevic, V., Ramic, Z., and M. Mostarica-Stojkovic (2002). Down-regulation of experimental allergic encephalomyelitis in DA rats by tiazofurin. *J. Neuroimmunol.* **130**, 66-77.
- Voskuhl, R.R., Peterson, R.S., Song, B., Ao, Y., Morales, L.B., Tiwari-Woodruff, S., and M.V. Sofroniew (2009). Reactive astrocytes form scar-like perivascular barriers to leukocyte during adaptive immune inflammation of the CNS. *J. Neurosci.* **29**, 11511-11522.
- Weber, G. (2005). Down-regulation of increased signal transduction capacity in human cancer cells. *Adv. Enzyme Regul.* **45**, 37-51.
- Williams, A., Piaton, G., and C. Lubetzki (2007). Astrocytes--friends or foes in multiple sclerosis? *Glia* **55**, 1300-1312
- Wu, J., Ohlsson, M., Warner, E.A., Loo, K.K., Hoang, T.X., Voskuhl, R.R., and L.A. Havton (2008). Glial reactions and degeneration of myelinated processes in spinal cord gray matter in chronic experimental autoimmune encephalomyelitis. *Neuroscience* **156**, 586-596.