

*Ivana I. Mirkov*<sup>1</sup>, *Milena V. Kataranovski*<sup>1,2</sup>,  
*Marina D. Soković*<sup>1</sup>, *Jasmina M. Glamočlija*<sup>1</sup>,  
*Lidija D. Zolotarevski*<sup>3</sup>, *Dragan S. Kataranovski*<sup>1,2</sup>

<sup>1</sup> Institute for Biological Research “Siniša Stanković”,  
Bulevar despota Stefana 142, Belgrade, Serbia

<sup>2</sup> Faculty of Biology, University of Belgrade, Studentski trg 16, Belgrade, Serbia

<sup>3</sup> Military Medical Academy, Crnotravska 11, Belgrade, Serbia

## EXPERIMENTALLY INDUCED INVASIVE ASPERGILLOSIS IN MICE

**ABSTRACT:** In this study systemic response to intravenous administration of *Aspergillus fumigatus* conidia was investigated. The intensity of response was evaluated by a survival rate and by histopathological tissue analysis. Administration of all doses ( $10^6$  —  $5 \times 10^7$ ) of *Aspergillus fumigatus* conidia caused mortality, but the highest mortality and the shorter time of survival were noted at higher doses applied. At the highest applied dose, the presence of spores and hyphae was noted in lungs and kidneys. Histological analysis revealed the presence of intense inflammatory reaction in lungs, kidneys and spleen. Functional and histological changes observed provide means to study both mechanisms and drug interventions in systemic *Aspergillus* infection.

**KEY WORDS:** *Aspergillus fumigatus*, mice, systemic aspergillosis, urinary obstruction

### INTRODUCTION

Species of genus *Aspergillus* are representatives of saprophytic filamentous fungi found in most environments. The most common species of *Aspergillus* causing invasive diseases include *A. fumigatus*, *A. flavus*, *A. niger*, *A. clavatus*, *A. glaucans*, *A. nidulans*, *A. terreus* and *A. versicolor*. *Aspergillus* sp. is weak pathogen, but might cause a disease in an immunocompromised host. Aspergillosis comprises a variety of infection, manifestation including invasive aspergillosis, pulmonary aspergilloma and allergic bronchopulmonary aspergillosis (D e n n i n g, 1998). Diseases that cause *A. fumigatus* are very difficult to diagnose, because the most diagnostic features are not specific, and patients are usually asymptomatic.

Animal experimental models offer an approach for *Aspergillus* infection studies. By using animal individuals, with defenses impaired by glucocorticoids, cyclophosphamide etc. (immunosuppressed animals), valuable informa-

tion concerning pathogenesis of *Aspergillus* infections was obtained. Studies on immunocompetent hosts, on the other hand enable investigations of the mechanisms of resistance to *Aspergillus*.

In this study we investigated a response to systemically applied *A. fumigatus* conidia. With this aim, survival and histopathology of distinct organs were analyzed, following the intravenous injection of conidia.

## MATERIALS AND METHODS

Conventionally housed female C57BL/6 mice, eight to twelve weeks old, are used in the experiments. Animals were housed under constant conditions (temperature 19—21°C, daily-night rhythm 12 h), with food and water *ad libitum*. The experiments were conducted with adherence to Ethical Committee of Institute for Biological Research “Siniša Stanković”.

*A. fumigatus*, human isolate, from the Institute of public health of Serbia “Dr Milan Jovanović Batut” was subcultured on standard mycological slants (Booth, 1971). Inoculum was prepared by flooding the surface of agar slants with sterile 0,85% NaCl with 0,1% Tween 80. The suspension of spores was prepared in apyrogenic sterile physiological saline and doses of  $1 \times 10^6$ ,  $1 \times 10^7$  and  $5 \times 10^7$  conidia were applied intravenously into each mouse. The control mice received saline solely.

Animals were inspected two times a day. All mice were observed for a total 14 days after the infection. Mice that survived until the day 14, were euthanized.

Presence of fungi in organism of mice was established by histological analyses. Tissue specimens were fixed in 4% formalin (pH 6, 9). Fixed material was dehydrated in graded ethanol series. Material is then embedded in paraffin at 57°C. Sections 5  $\mu\text{m}$  thick, were stained with hematoxylin-eosin (H & E).

Specific gravity, protein and haemoglobin content in urine were determined by test strips Combur<sup>10</sup> Test<sup>®</sup>M (Roche Diagnostics GmbH, Germany) as parameters of renal function.

Results were statistically processed by Mann-Whitney U test. As significant was considered  $p < 0,05$ .

## RESULTS AND DISCUSSION

All doses of applied conidia induced mortality in experimental animals. Mortality rate was proportional to the injected inoculum. Inoculation of  $1 \times 10^6$  and  $1 \times 10^7$  conidia per mouse caused mortality in 40 and 60% of mice respectively. Dose of  $5 \times 10^7$  conidia caused mortality in all treated animals, by day five following inoculation (Figure 1). Higher doses also reduced time of survival (the higher dose, the shorter time of survival). Mortality/survival data are in accordance with the study showing high mortality at the dose of  $10^7$  of infected immunocompetent mice (Cenci et al., 1997).

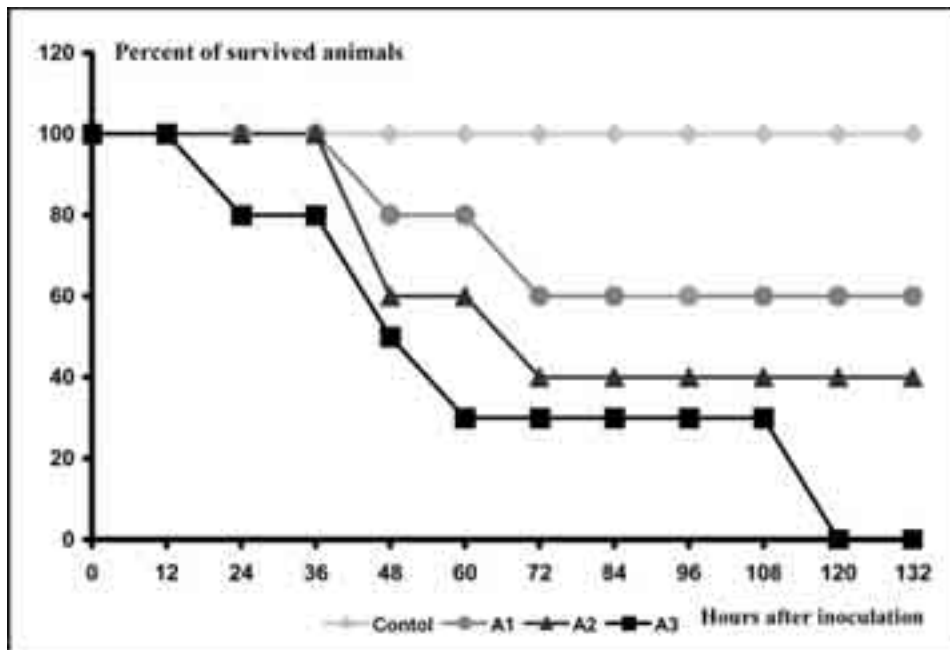


Fig. 1 — Survival curve (A1 — mice inoculated with  $1 \times 10^6$  conidia of *A. fumigatus*; A2 — mice inoculated with  $1 \times 10^7$  conidia; A3 — mice inoculated with  $5 \times 10^7$  conidia)

Presence of infection was assessed by observation of animal prostration. Pronounced hypodynamic state and piloerection were noted in infected mice, in accordance with the data from the studies of invasive aspergillosis in mice (D u o n g et al., 1998). Mice in hypodynamic state died shortly after these signs appeared.

Histological data revealed the presence of inflammatory pulmonary response (presence of lymphocytes in peribronchial and/or perivascular sites) in all experimental groups. Microabscesses were noted in lungs, liver, kidneys and spleen of animals. In animals which received the highest dose the presence of conidia and hyphae in lungs and kidneys was noted.

Renal aspergillosis, at highest dose was accompanied with compromised renal function as judged by the changes in selected urinary parameters (Figure 2). In all control individuals, specific gravity values were 1,015 (test strips values ranged from 1,000 to 1,030). In 62% of treated mice, this value was 1,030, and in the rest value of 1,025 was detected. Difference between the control and treated groups is statistically significant ( $p = 0,0066$ ). Significantly increased haemoglobinuria ( $p = 0,023$ ), and a tendency of increase in urine protein content ( $p = 0,089$ ), were noted in treated individuals. Renal dysfunction observed in these animals, is in agreement with the studies which showed that kidneys are the primary target organs for intravenous *A. fumigatus* infection (L a t g e, 1999) in animals and humans, and with reports which de-

monstrated urinary obstruction as a consequence of renal infection detected in humans (De Medeiros, 1999; Bisi, 2003).

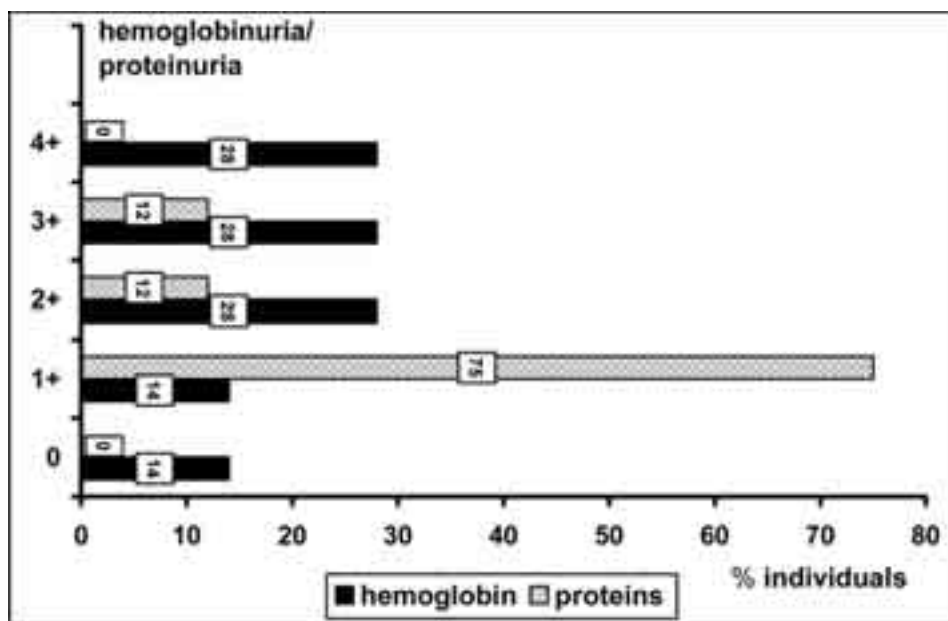


Fig. 2 — Hamoglobin/protein values in infected individuals

## CONCLUSION

In conclusion, presented data demonstrated both functional and histological changes in organs of mice following systemic application of *A. fumigatus*. This model might provide means to study mechanisms of invasive aspergillosis, as well as drug testing in preclinical trials.

## ACKNOWLEDGMENTS

This study was supported by the Ministry of Science and Environmental Protection, Grant# 143038.

## LITERATURE

- Bisi, M., Palou, J., Segarra, J., Salvador, J. and Villavicenco, H. (2003): *Percutaneous treatment of a primary renal aspergilloma in patient with AIDS*, Arch Ital Urol Androl 75: 119—123.
- Booth, C. (1971): *Fungal culture media*. In: *Methods in Microbiology 4*, Ed JR Norris, DW Ribbons, Academic Press, London & New York 49—94.

- Cenci, E., Perito, S., Enssle, K. H., Mosci, P., Latge, J. P., Romani, L. and Bistoni, F. (1997): *Th1 and Th2 cytokines in mice with invasive aspergillosis*, *Infect. Immun* 65: 564—570.
- De Medeiros, C. R., Dantas da Cunha, Jr. A., Pasquini, R. and Arns da Cunha, C. (1999): *Primary renal aspergillosis: extremely uncommon presentation in patients treated with bone marrow transplantation*, *Bone Marrow Transplant* 24: 113—114.
- Denning, D. W. (1998): *Invasive aspergillosis*, *Clin Infect Dis* 26:781—805.
- Duong, M., Ouellet, N., Simard, M., Bergeron, Y., Olivier, M. and Bergeron, M. G. (1998): *Kinetic study of host defense and inflammatory response to Aspergillus fumigatus in steroid-induced immunosuppressed mice*, *J. Infect. Dis.* 178: 1472—82.
- Latge, J. P. (1999): *Aspergillus fumigatus and aspergillosis*, *Clin. Microbiol. Rev.* 12(2): 310—350.
- Stevens, D. A., Kan, V. L., Judson, M. A., Morrison, V. A., Dummer, S., Denning, D. W., Bennett, J. E., Walsh, T. J., Patterson, T. F. and Pankey, G. A. (2000): *Practice guidelines for diseases caused by Aspergillus*, *Clin. Infect. Dis.* 30:696—709.

#### ЕКСПЕРИМЕНТАЛНО ИНДУКОВАНА АСПЕРГИЛОЗА КОД МИШЕВА

Ивана И. Мирков<sup>1</sup>, Милена В. Катарановски<sup>1, 2</sup>,

Марина Д. Соковић<sup>1</sup>, Јасмина М. Гламочлија<sup>1</sup>,

Лидија Д. Золотаревски<sup>3</sup>, Драган С. Катарановски<sup>1, 2</sup>

<sup>1</sup> Институт за биолошка истраживања „Синиша Станковић”,

Булевар деспота Стефана 142, Београд, Србија

<sup>2</sup> Биолошки факултет, Универзитет у Београду,

Студентски трг 16, Београд, Србија

<sup>3</sup> Војно-медицинска академија, Црнотравска 11, Београд, Србија

#### Резиме

*Aspergillus fumigatus* је опортунистичка гљива која се може наћи у свим срединама. Опортунистичке гљиве проузрокују појаву болести код имунокомпромитованих особа, односно код особа са ослабљеним имунским системом. Најчешће болести које изазива *A. fumigatus* су: плућна аспергилоза, аспергиломи и алергијска бронхопулмонарна аспергилоза. Ове болести су тешке за дијагнозу јер су симптоми неспецифични.

Интравенска апликација конидија *Aspergillus fumigatus* изазива промене у преживљавању и понашању животиња. Са повећањем концентрације конидија смањује се време преживљавања. Највећа апликована доза ( $5 \times 10^7$  конидија) доводи до угинућа свих животиња до петог дана након инокулације. Инфициране животиње карактеришу промене у понашању (акинезија, атонија) и пилоерекција.

Хистолошком анализом је показано присуство интензивне запаљењске реакције у плућима, бубрезима и слезини третираних јединки, као и присуство спора и хифа у бубрезима и плућима јединки које су примиле највећу дозу *A. fumigatus*. Код ових јединки запажен је и поремећај бубрежне функције на основу промена у специфичној тежини урина, рН вредности, присуству протеинурије и хемоглобинурије.